External Skeletal Fixation in Small Animal Fracture Repair

Russell Yeadon

Vets Now Referrals, Swindon

www.vets-now.com

Vetsnow

Improving the lives of vets & pets

Sponsor this evening

VETERINARY INSTRUMENTATION

A HENRY SCHEIN® COMPANY

Vetsnow

Improving the lives of vets & pets

INTRODUCTION

Fracture planning

- Relies on understanding of different mechanisms of bone healing
- Prediction of predominant mode of bone healing for any given fracture determines:
  - rate of bone healing
  - degree of stability required
- Management plan can then be determined

Why use an ESF?

Plan

- Quick review of bone biology
  - Direct healing
  - Indirect healing
- External Skeletal Fixation
  - Major types, configurations and mechanics
  - Application techniques
- Examples of different applications

Bone biology

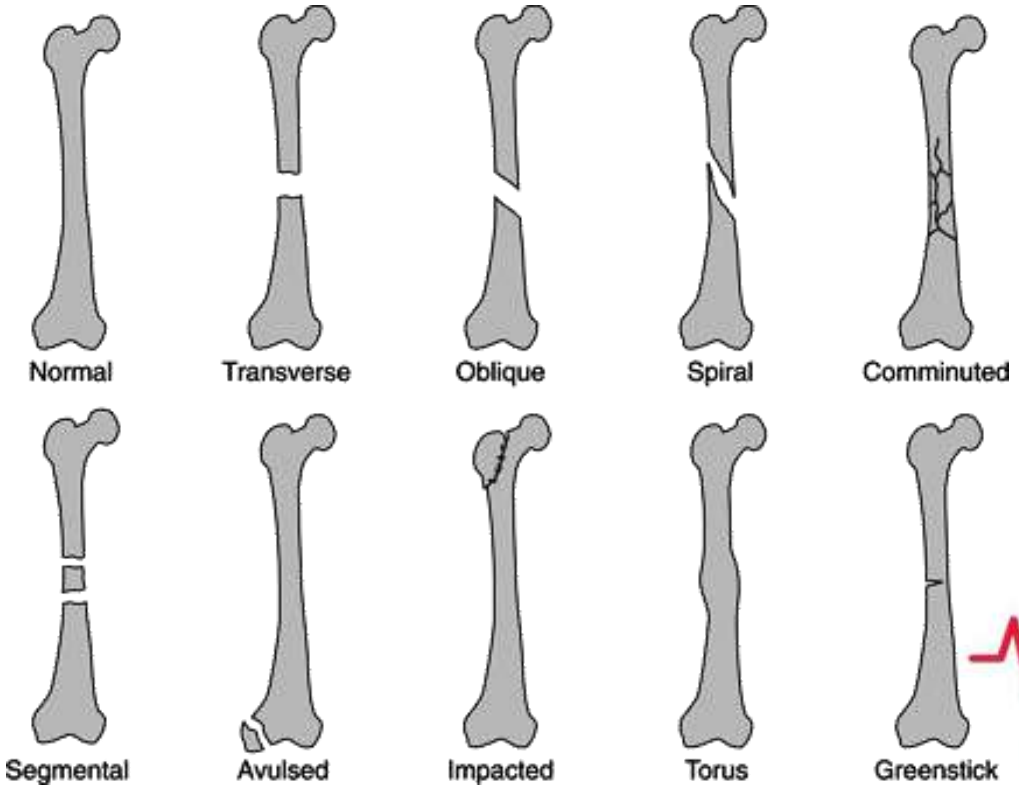

Stages of fracture healing

Inflammation

Repair

Remodeling

Mechanisms of bone formation

3 main types of bone formation – different involvement in different types of bone healing:

1. Cutting cones
2. Intramembranous bone formation
3. Endochondral bone formation

1. Cutting cones

- Cutting cones traverse fracture site
- Primarily a mechanism to remodel bone
- Osteoclasts at the front of the cutting cone remove bone
- Trailing osteoblasts lay down new bone
- Re-establish Haversian system

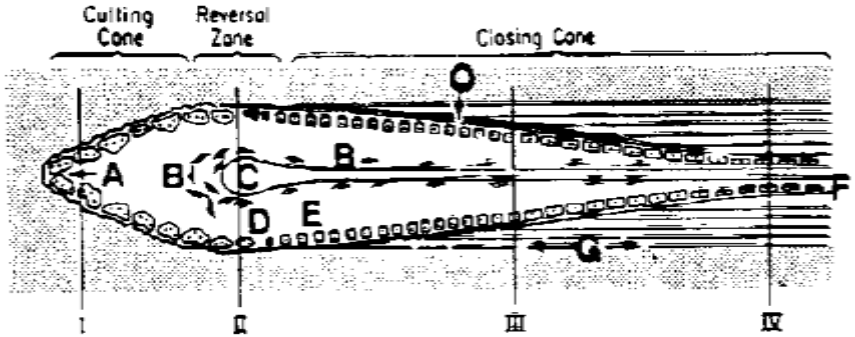

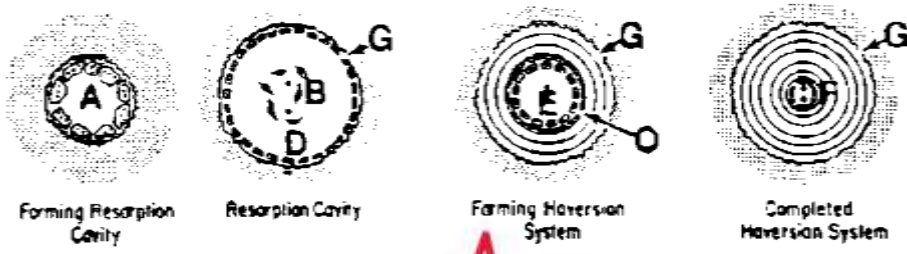

Haversian System

- Osteon with central Haversian canal containing
  - cells
  - vessels
  - nerves
- Volkmann's canal
  - connects osteons

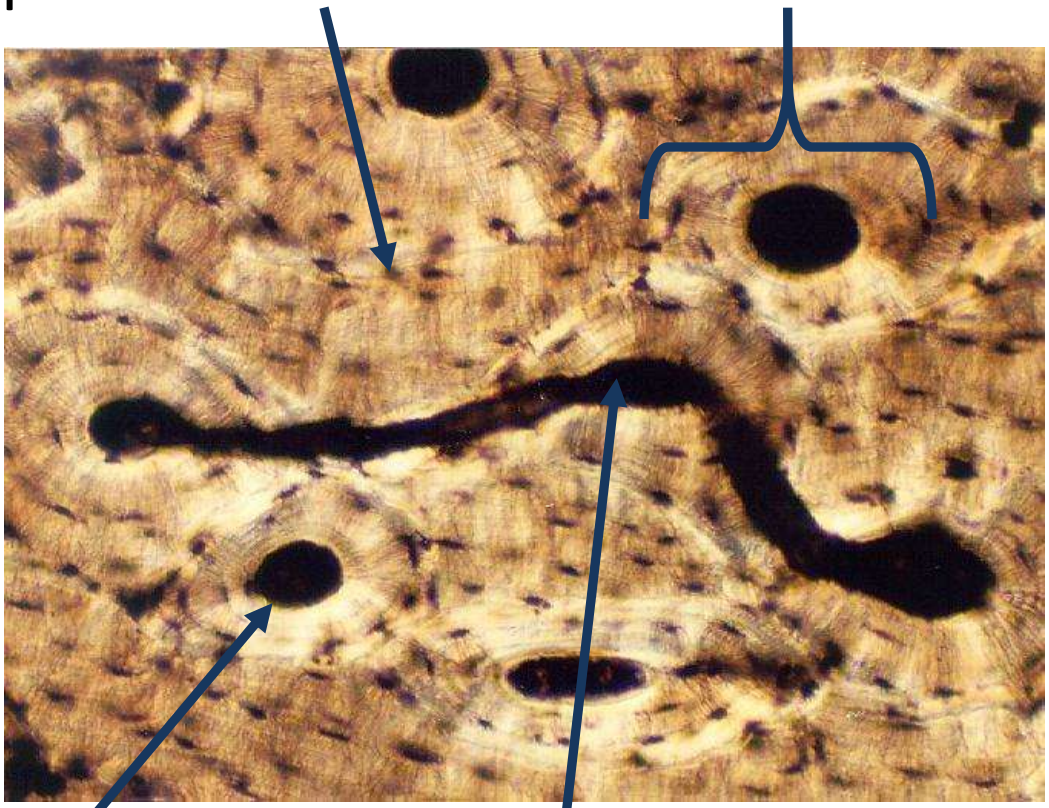

2. Intramembranous (periosteal) bone formation

- Mechanism by which long bone grows in <u>width</u>
- Osteoblasts differentiate directly from pre-osteoblasts (periosteum and endosteum) and lay down seams of osteoid
- Does NOT involve cartilage precursor / matrix

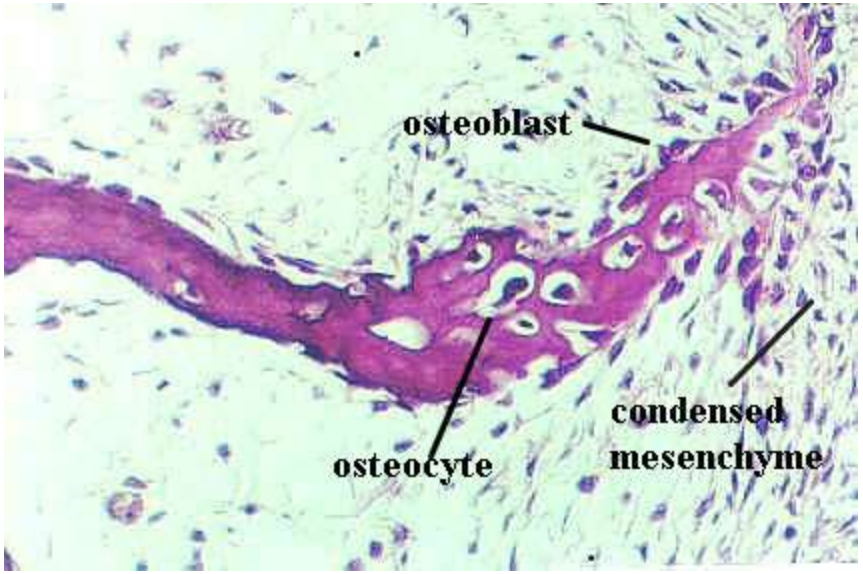

3. Endochondral bone formation

- Mechanism by which long bone grows in <u>length</u>
- Osteoblasts line a cartilage precursor
- Chondrocytes hypertrophy, degenerate and calcify (low oxygen tension)
- Vascular invasion of cartilage occurs followed by ossification (increasing oxygen tension)

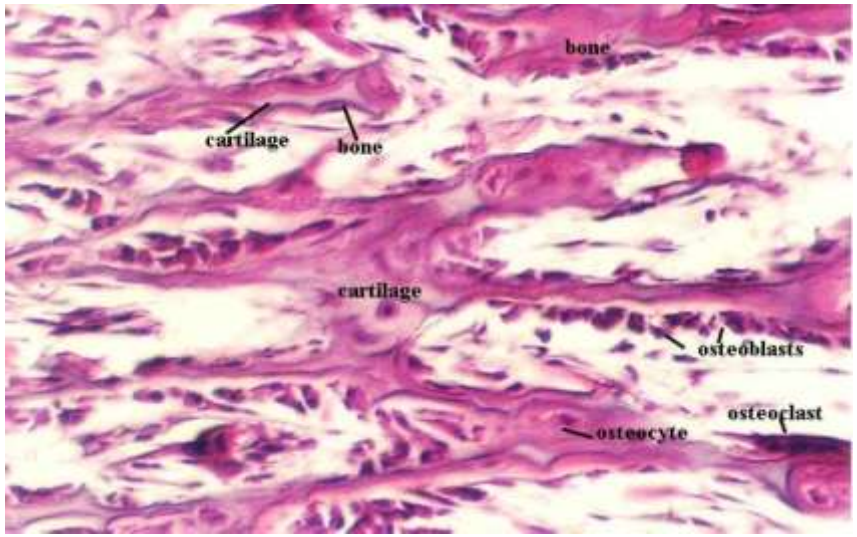

Bone healing

- 2 main subtypes, each with different involvement of the 3 bone formation methods

Primary (direct) healing

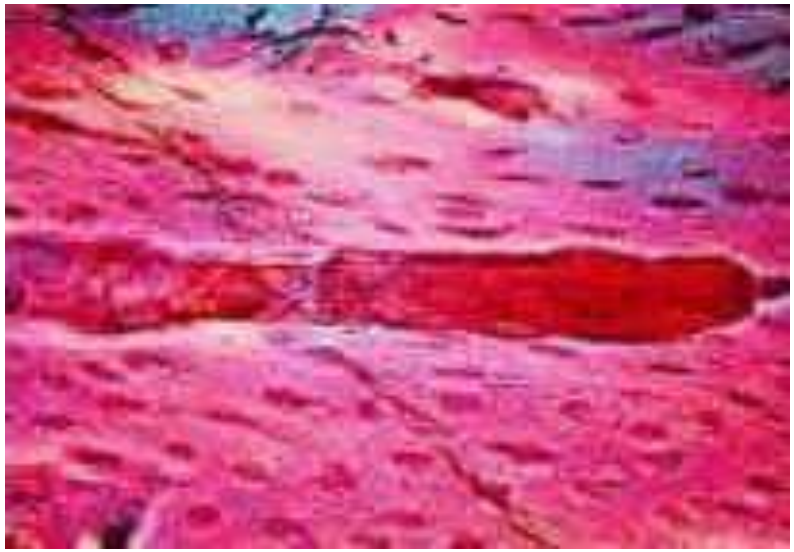

Secondary (indirect) healing

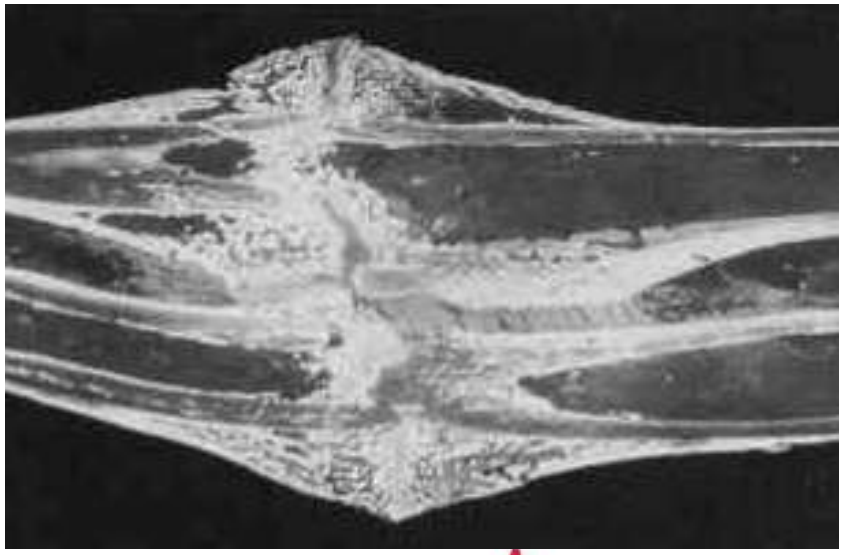

Primary (direct) bone healing

Orthopaedic carpentry

Primary (direct) bone healing

- Two subtypes
  A. Contact healing
     (no gap)
  B. Gap healing
     (<200-500µm gap)

- Both require absolute stability (<2% inter-fragmentary strain)

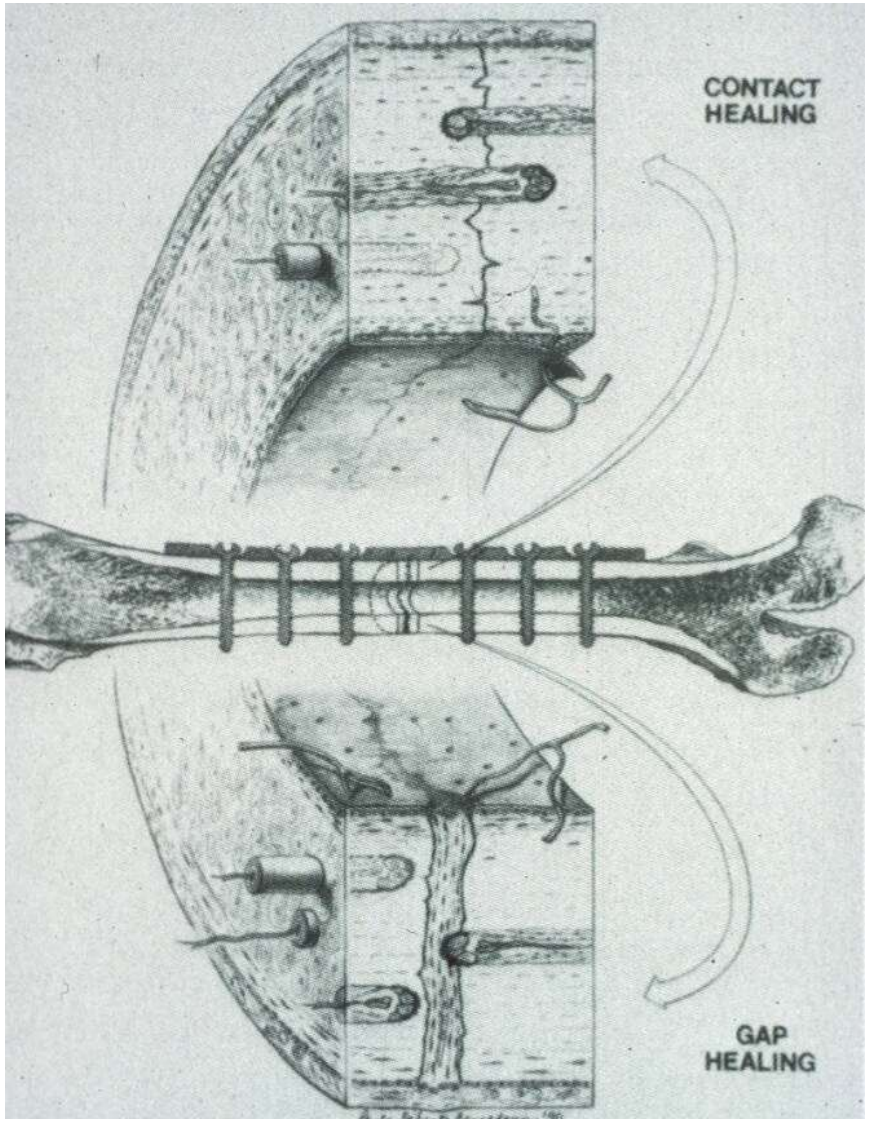

Definition

- Inter-fragmentary strain
  - Defined as the % deformation of the fracture gap

= [Distance of deformation ÷ original fracture gap] x100

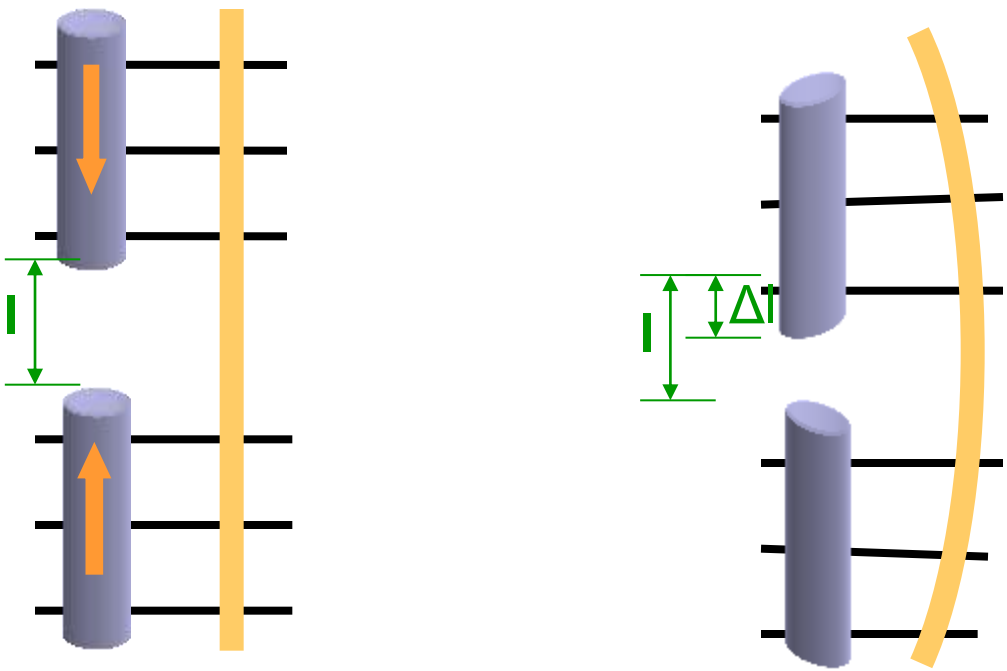

Strain (ε)

$\Delta l / l$

A. Contact healing

- Bone ends in direct contact
- Re-establishes cortical lamellar bone structure
  - Cutting cones cross fracture line
  - Leave osteon "pegs" crossing fracture line
  - Haversian system re-established
- Resorption and formation occur simultaneously
  - rate ~50µm per day
  - slow process (months-years)
- Begins immediately when local conditions appropriate (contact and stability)

B. Gap healing

- Fracture gap <200-500µm
- Gap fills with haematoma / loose connective tissue
- <2 weeks after fracture, vascular supply re-established
- Gap fills directly with woven bone
  - intramembranous ossification – direct recruitment / differentiation of osteoblasts
  - i.e. no cartilaginous anlage
- Woven bone gradually → lamellar bone by cutting cones (remodelling)

Traditional AO principles

1. Rigid internal fixation
2. Accurate anatomic reduction
3. Atraumatic operative technique
4. Early mobilization

- Aimed at maximising primary bone healing
- Permits load sharing between implants and reconstructed bone column

AO1. Rigid internal fixation

- Most fractures that have full open reduction should have rigid internal fixation

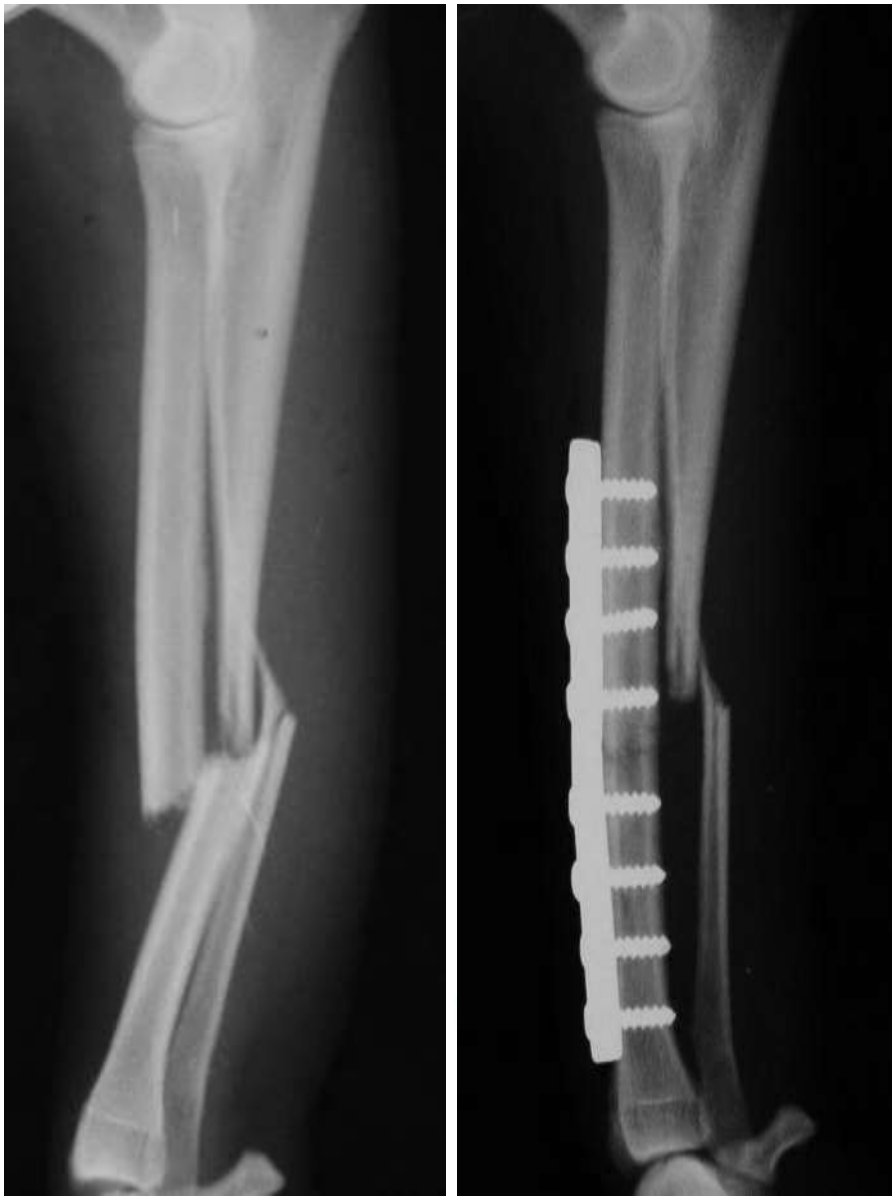

AO2. Anatomic reduction

- Important in articular fractures
- Avoid callus formation

AO3. Atraumatic operative technique

- Necessary for successful management of all fractures (and surgery in general)
- Halsted's principles
  a) gentle handling of tissue
  b) aseptic technique
  c) sharp anatomic dissection of tissue
  d) careful hemostasis
  e) obliteration of dead space
  f) avoidance of tension

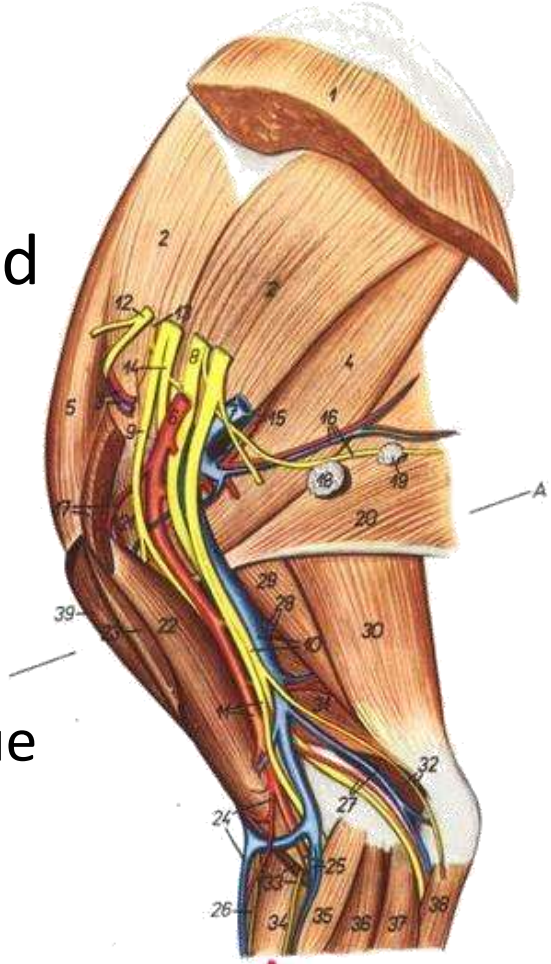

Limitations to direct bone healing

- Requires minimal / no fracture gap
  - Accurate reduction ± compression
- Requires absolute stability (<2% strain)
  - Rigid fixation (internal)
- Slow to achieve maximum strength
  - Durable fixation
  - Susceptible to failure for many months
  - Problematic if implant removal required

Is accurate anatomical reconstruction possible here?

Is bulky internal fixation desirable here?

Anatomic reduction

- Not necessary for all long bone fracture repair
- Cost/benefit ratio of reconstructing all the fragments
- Must preserve the neuro-vascular supply to bone and surrounding soft tissue

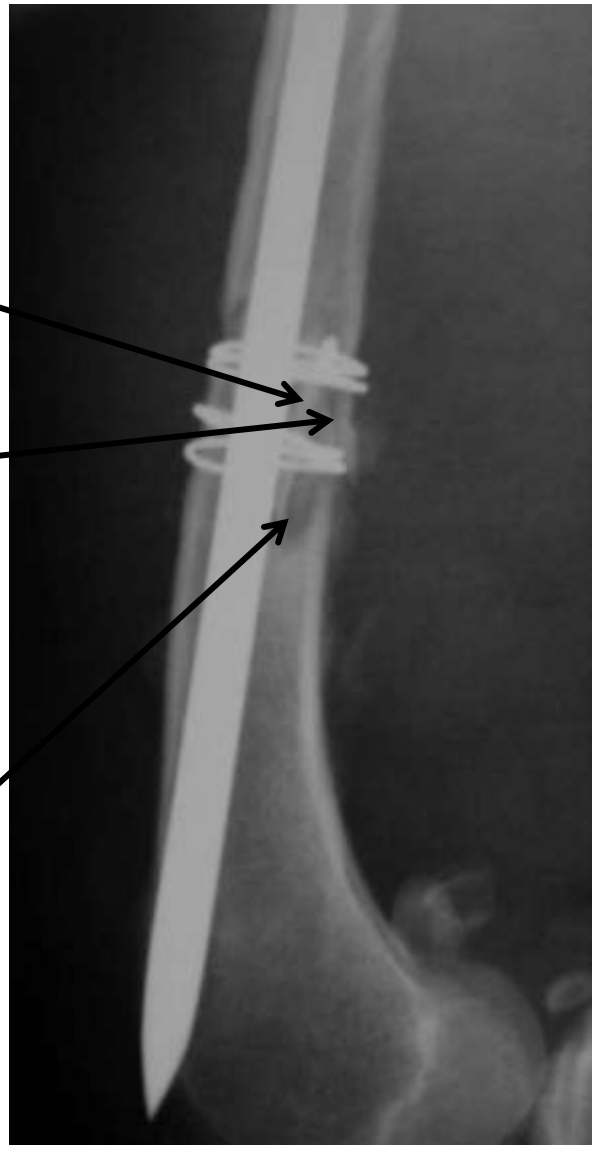

Anatomic redu

- Load sharing between reconstructed bone column and implants

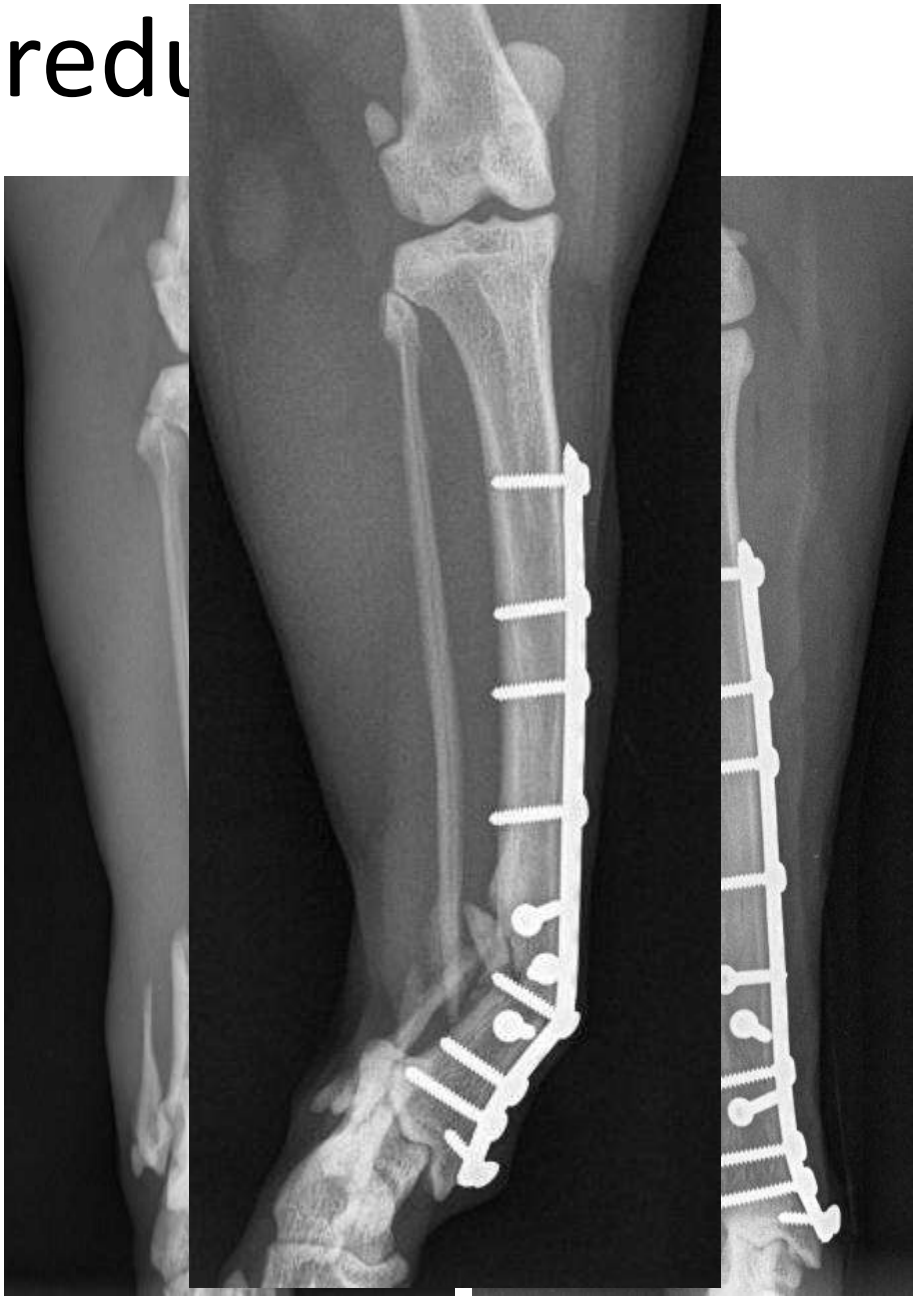

Indirect bone healing

Orthopaedic gardening

Indirect healing

1. Inflammation

- <u>Haematoma</u>
- Inflammatory cells cleanse fracture site of necrotic debris, bacteria, etc
- Vascular thrombosis → bony necrosis at edges of fracture
  - Increases fracture gap → decreases relative strain…
- Increased capillary permeability
- Release of inflammatory, angiogenic and osteoinductive factors
- Early granulation

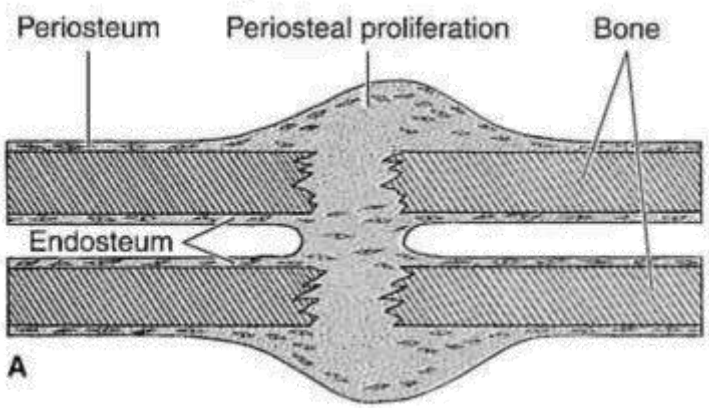

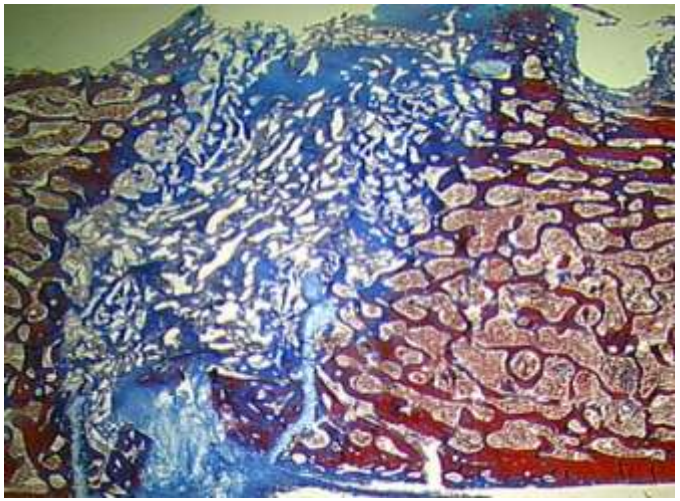

Indirect healing

2. Soft callus formation

- Endochondral ossification when inter-fragmentary strain <10%
  - Chondrocytes → type II collagen matrix (cartilage callus)
- Intramembranous ossification (periosteal callus)
- Soft callus starts to stabilise fracture,
  - ↑ instability → bigger callus

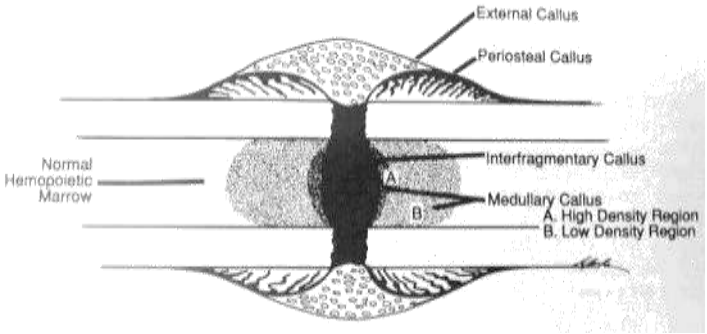

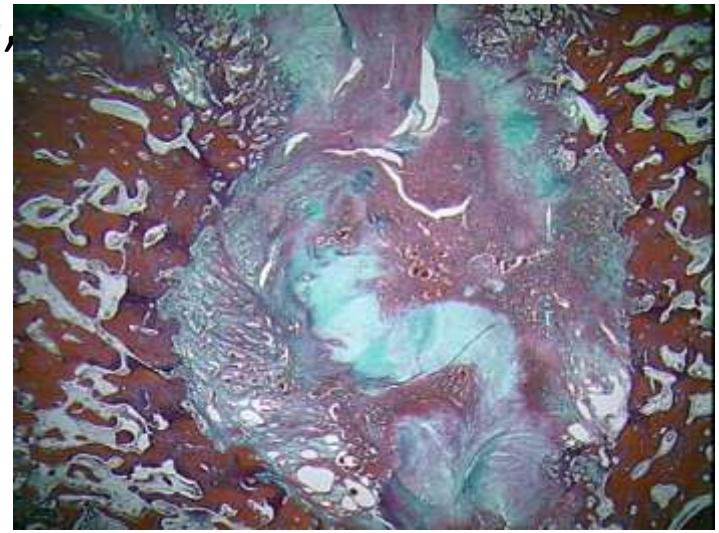

Indirect bone healing

3. Hard callus

- Endochondral ossification progresses as inter-fragmentary strain reduced to ~2%
  - cartilage callus converts to woven bone
- Intramembranous ossification progresses throughout periosteal callus

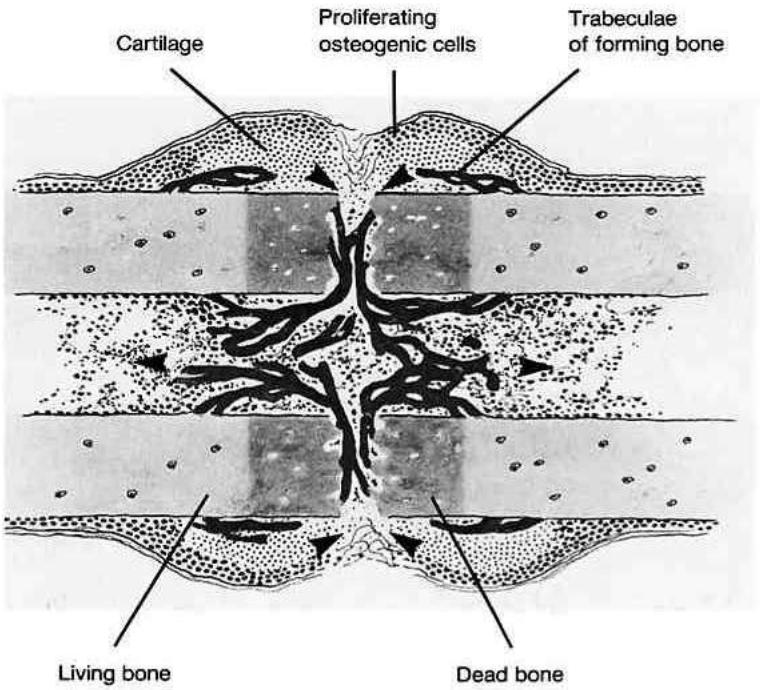

Indirect bone healing

4. Remodelling

- Cutting cones cross fracture site
  - remodel woven bone callus
  - re-establish lamellar bone cortices
- Intramedullary canal re-established
- Responds to Wolff's law (remodels in response to mechanical stimuli)

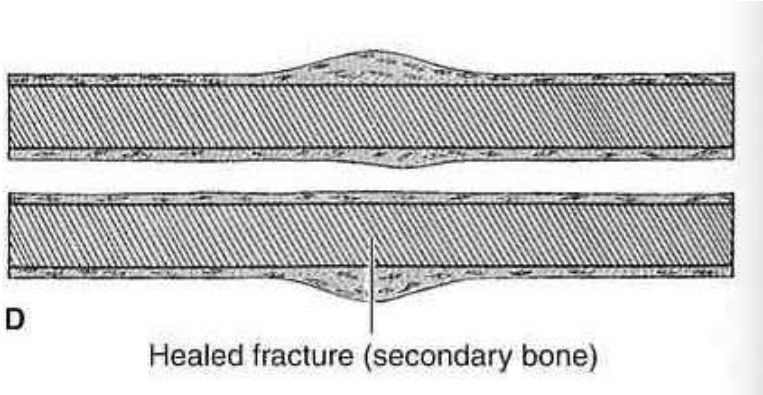

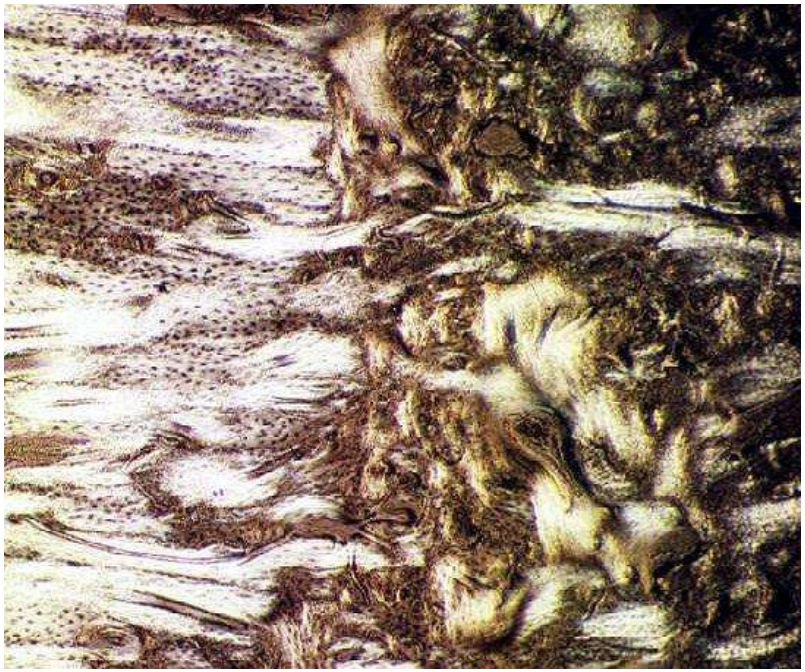

Biologic fracture management

- Atraumatic surgical technique top priority
- Preserve vitality of bones and soft tissue
  - Neurovascular supply
  - Periosteum
  - Endosteum
- Preserve fracture haematoma
  - chemical mediators
  - early soft callus

Table 2 Temporal and functional characteristics of members of the TGF-β superfamily observed during fracture healing in animal models

Member of the TGF-β superfamily	Time of expression	Specific responses in vivo and in vitro
GDF-8	Restricted to day 1[20]	Potential function as a negative regulator of skeletal muscle growth[20]
BMP-2	Days 1–21[10,20] (the earliest gene to be induced and second elevation during osteogenesis)	Recruitment of mesenchymal cells Chondrogenesis May initiate the fracture healing cascade and regulate the expression of other BMPs BMP-2, -6, -9 may be the most potent to induce osteoblast lineage-specific differentiation of MSCs[19]
BMP-3, -8	Days 14–21[20] (restricted expression during osteogenesis)	Temporal data suggest a role in the regulation of osteogenesis
BMP-4	Transient increased expression in the surrounding soft tissues 6 h to day 5[9] Days 14–21[20] Through out fracture healing[10]	Involvement in the formation of callus at a very early stage in the healing process In vitro: BMP-3 and -4 stimulate the migration of human blood monocytes[63]
BMP-7	Days 14–21[20] From the early stages of fracture healing[9]	Regulatory role in both types of ossification In vitro: stimulation of relative mature osteoblasts[19]
GDF-10, BMP-5, -6	Days 3–21[20]	Regulatory role in both types of ossification BMP-6 may initiate chondrocyte maturation[20]
GDF-5, 1	Day 7 (maximal) to day 14[20] (restricted expression during chondrogenic phase) GDF-1 at extremely low levels	GDF-5 an exclusive involvement in chondrogenesis is suggested Stimulation of mesenchymal aggregation and induction of angiogenesis through chemotaxis of endothelial cells and degradation of matrix proteins
GDF-3, GDF-6, 9	No detectable levels within the fracture callus[20]	GDF-6 may be expressed only in articular cartilage[20] and with GDF-5, 7 more efficiently induce cartilage and tendon-like structures in vivo[28]
TGF-β1, -β2, -β3	Days 1–21[20] Days 3–14[20] Days 3–21[20]	Potent chemotactic for bone forming cells and macrophages Proliferation of undifferentiated mesenchymal and osteoprogenitor cells, osteoblasts, chondrocytes

Many inflammatory, angiogenic and osteoinductive factors expressed early in healing process

Biologic fracture management

AO principles		Biologic principles
• Rigid internal fixation	→	• Adequate fixation
• Accurate anatomic reduction	→	• Accurate bone axial / length orientation
• Atraumatic operative technique	→	• Atraumatic operative technique
• Early mobilization	→	• Early mobilization

- Not new concept
- Reprioritizes AO principles

Biologic fracture management

- Optimise secondary (indirect) bone healing
  - Requires less rigid stabilisation
    - Callus development →additional stabilisation
  - No load sharing by bone column initially – need strong stabilisation
  - BUT faster than primary (direct) healing so need less durable stabilisation

Biologic fracture management

- Interlocking nail
- Plate / screws (bridging plate)

Biologic fracture management

- ESF
- ESF + IM pin

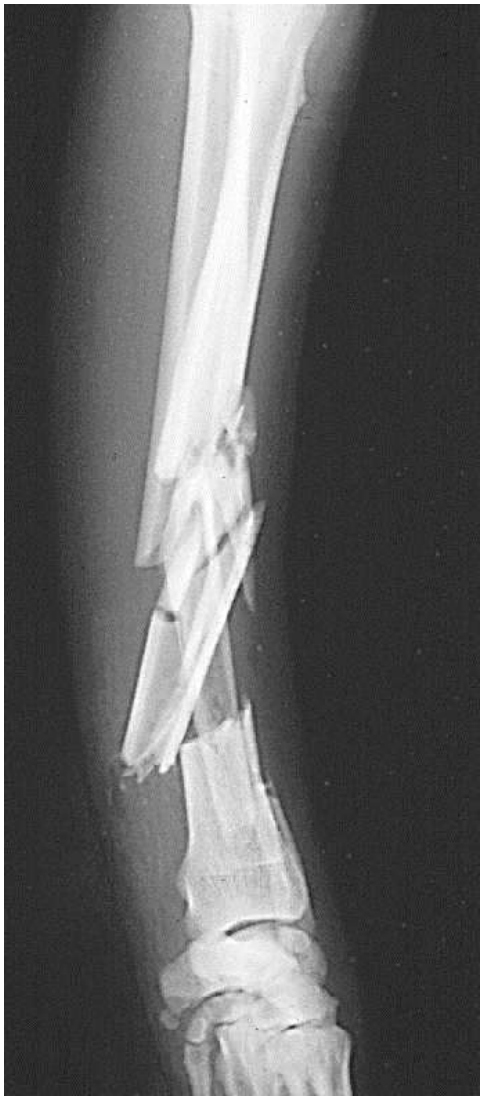

Fracture forces – a reminder

Tension



Rotation

Bending

Axial compression

EXTERNAL SKELETAL FIXATION

An Introduction

Plan

- Quick review of bone biology
  - Direct healing
  - Indirect healing
- External Skeletal Fixation
  - Major types, configurations and mechanics
  - Application techniques
- Examples of different applications

ESF

- Transcutaneous fixation pins inserted into bone
  - connected by external rods, bars, or columns

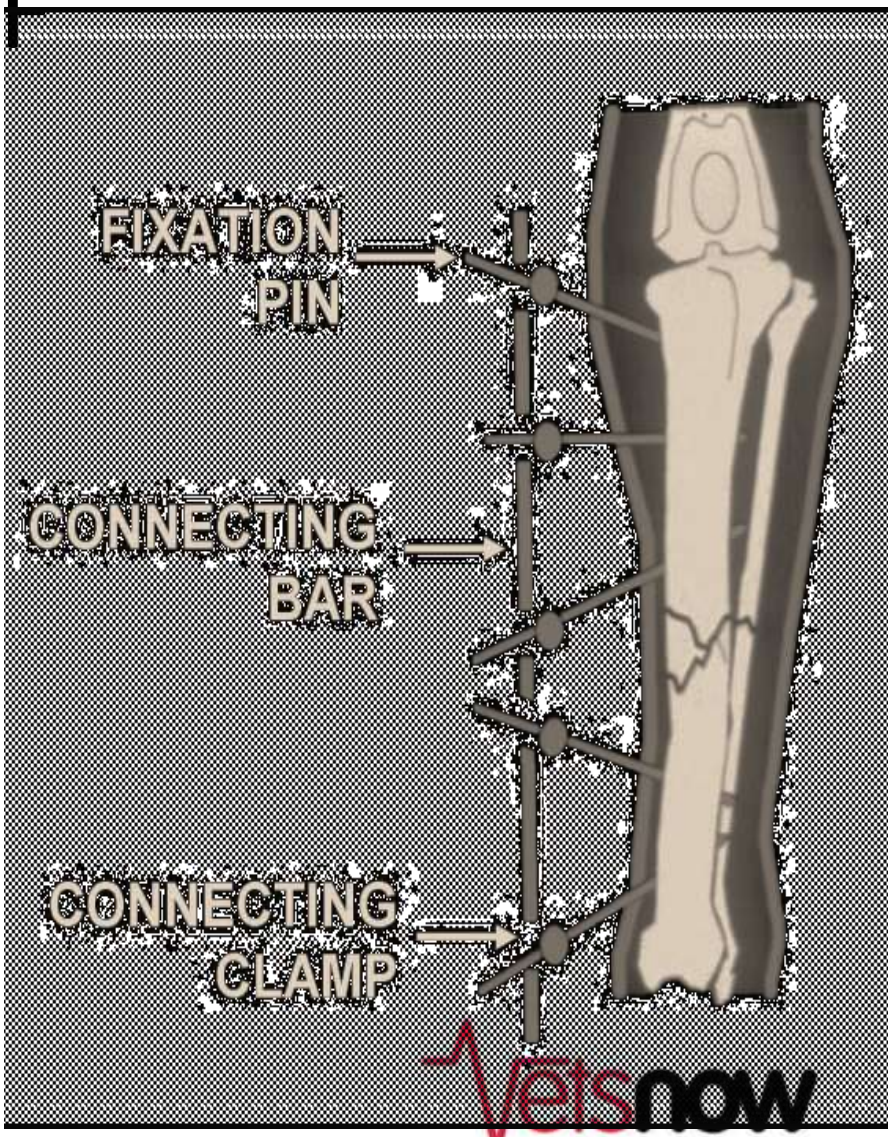

Advantages of ESF

- Rigidity versatile depending on construct
- No implants at fracture site
- Applied closed or through minimal approach
  - no disturbance of soft tissues
- Versatile construction for varying anatomy / fracture configuration
- Can be combined with other fixation methods
- No residual implants (removed at fracture union)

Types of ESF

- Linear
- Ring
- Acrylic / freeform
- [Pinless]

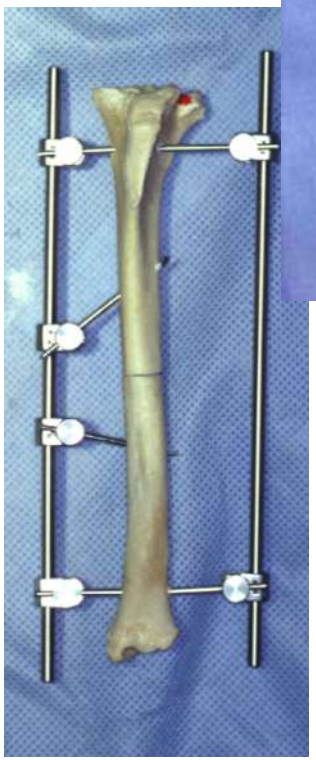

Linear ESF

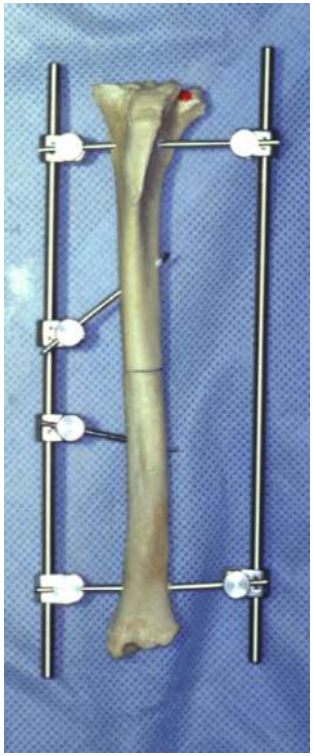

ESF Components

- Fixation pins/wires
- Connecting bars/rods
- Connecting clamps
- Special components

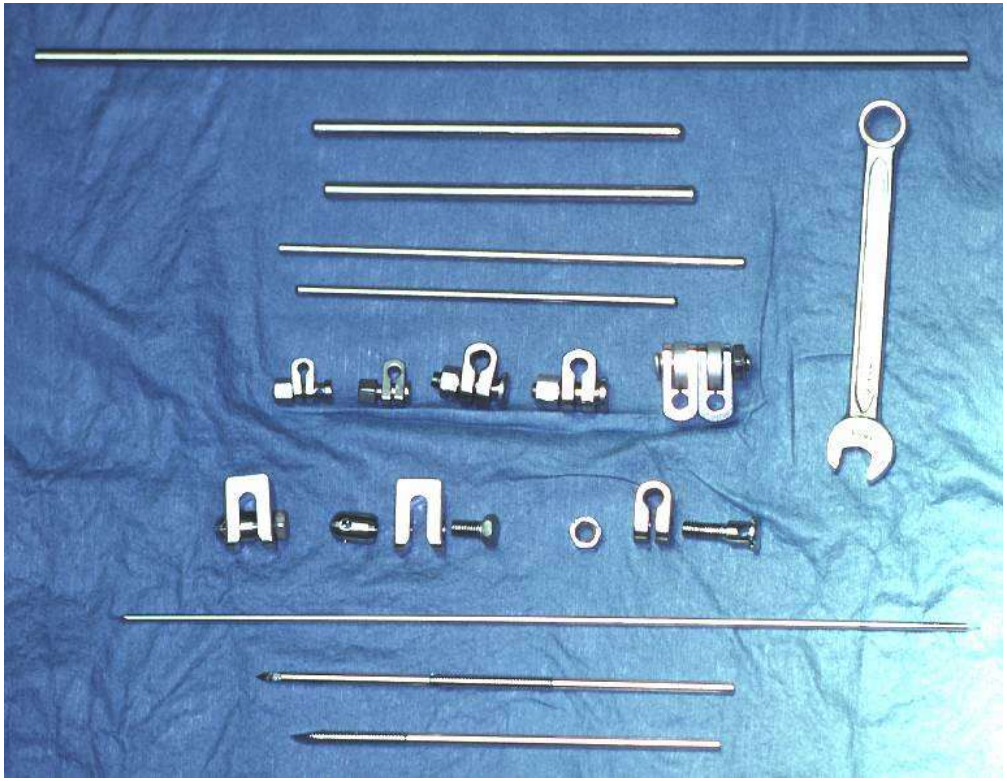

Fixation pins / wires

- Smooth
- Threaded
  - End
  - Central
  - Positive profile
  - Negative profile

- Half pin
- Full pin
- Wires
- ALL penetrate BOTH cortices of the bone

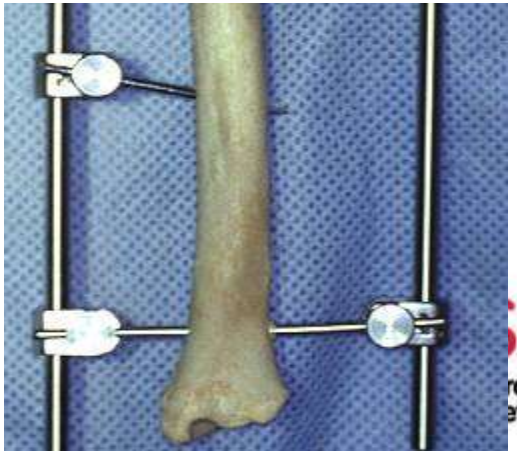

Connecting bars

- Stainless steel
- Aluminum
- Titanium
- Carbon fiber

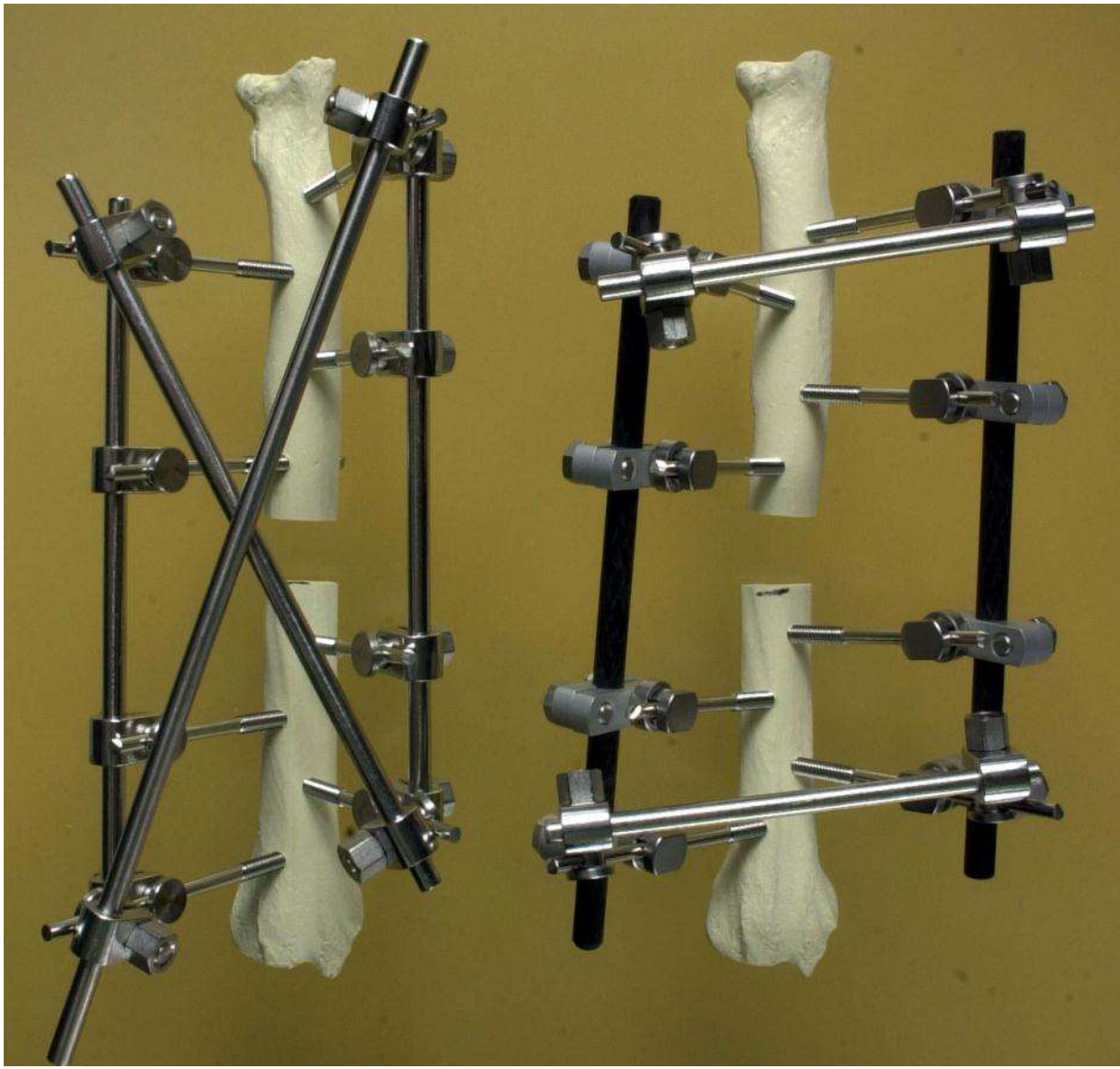

Clamps

- Single
  - Pin to rod
- Double
  - Rod to rod
- Acrylic / resin boluses

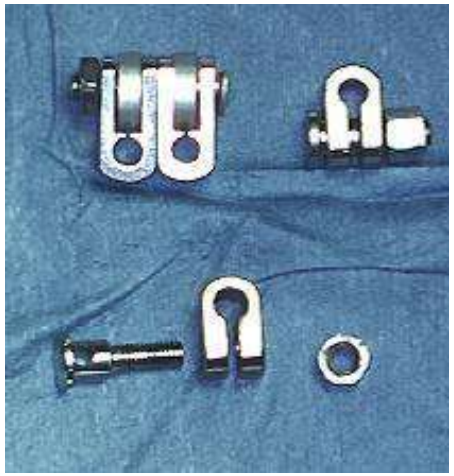

Kirschner-Ehmer

Imex SK

Securos



Meynard

Synthes

IMEX SK External Fixation System

- Accepts varied fixation pin diameter (including positive profile pins)
- Can be assembled and disassembled independent of frame construct



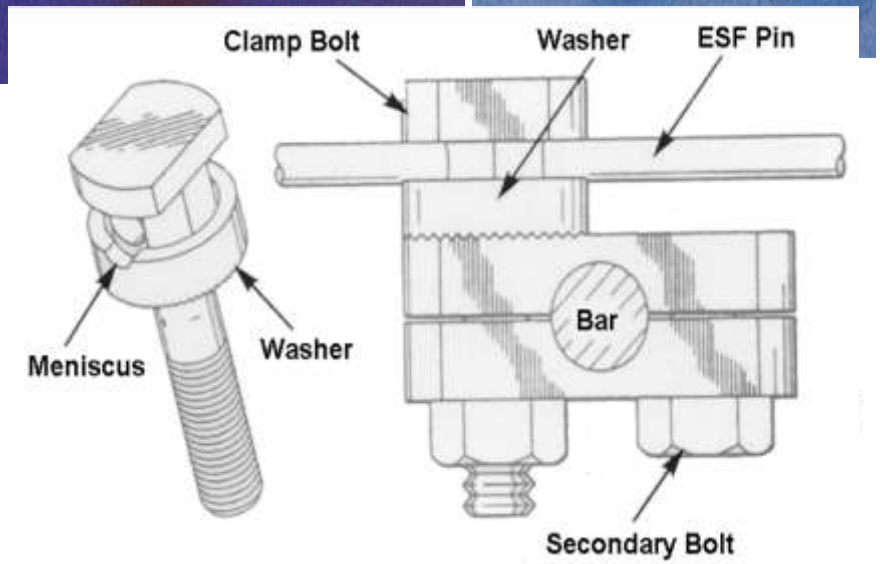

Type I

Type 1A

- Unilateral uniplanar

Type 1B

- Unilateral biplanar

Least rigid frame types

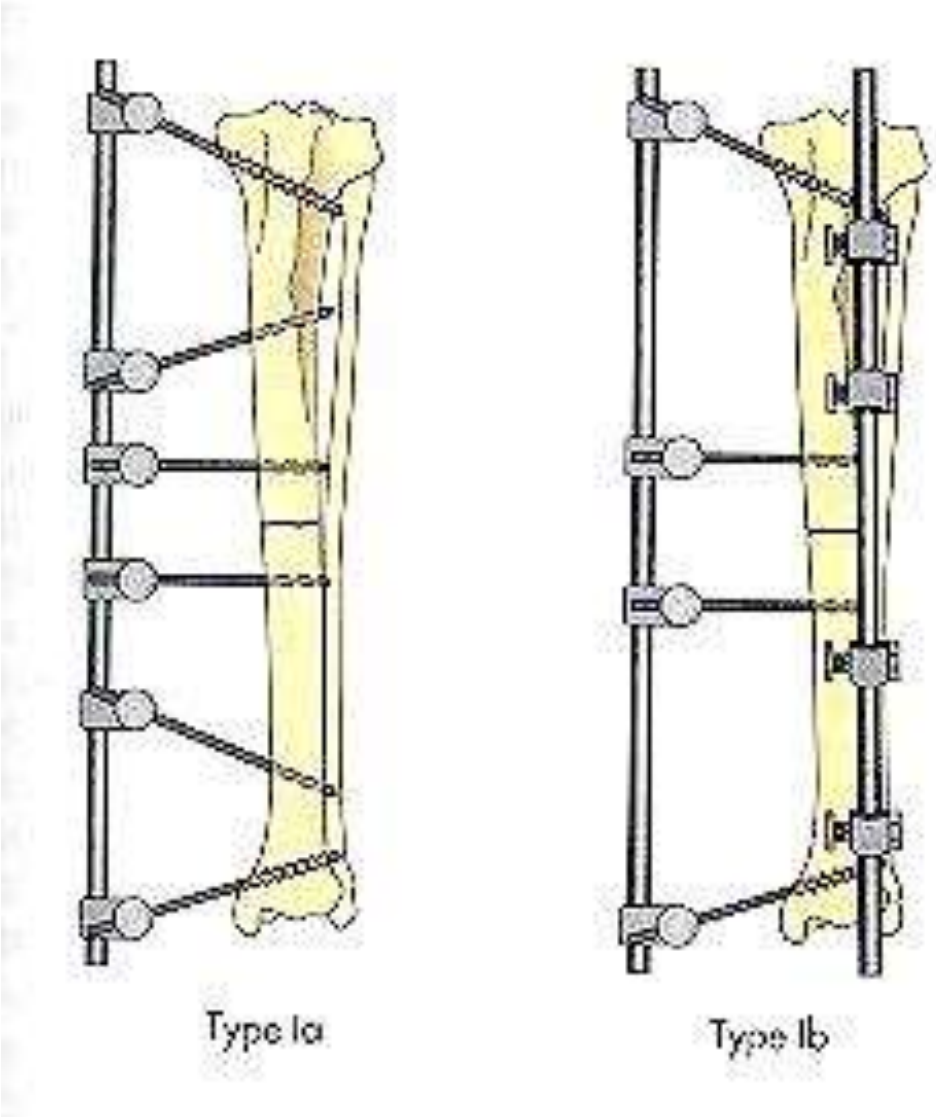

Type II

- Bilateral uniplanar
- Full pins

- May include additional half pins
- Limited to use below elbow / stifle
- More rigid than type 1

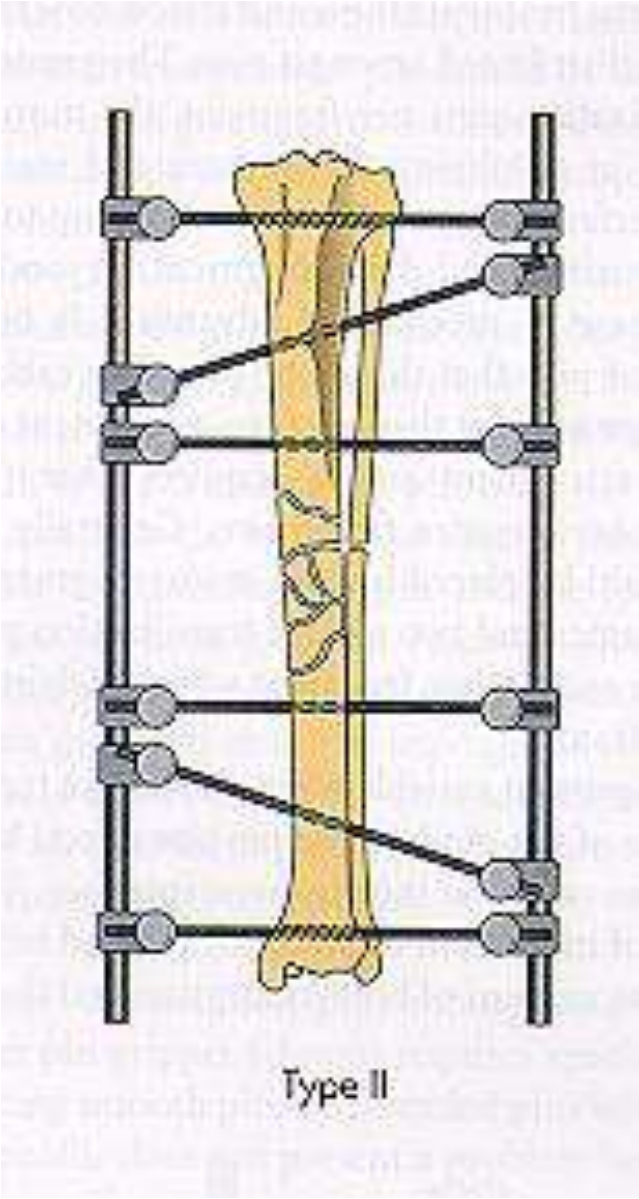

Type III

- Bilateral biplanar
- I + II = III

- Most rigid linear frame

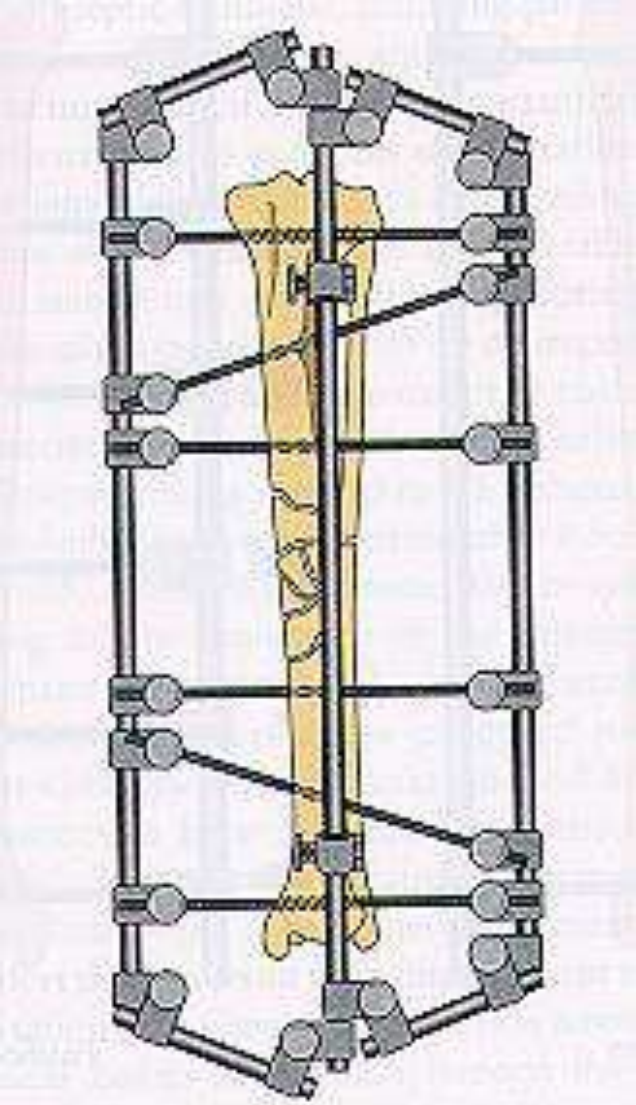

Type III

Increasing ESF rigidity

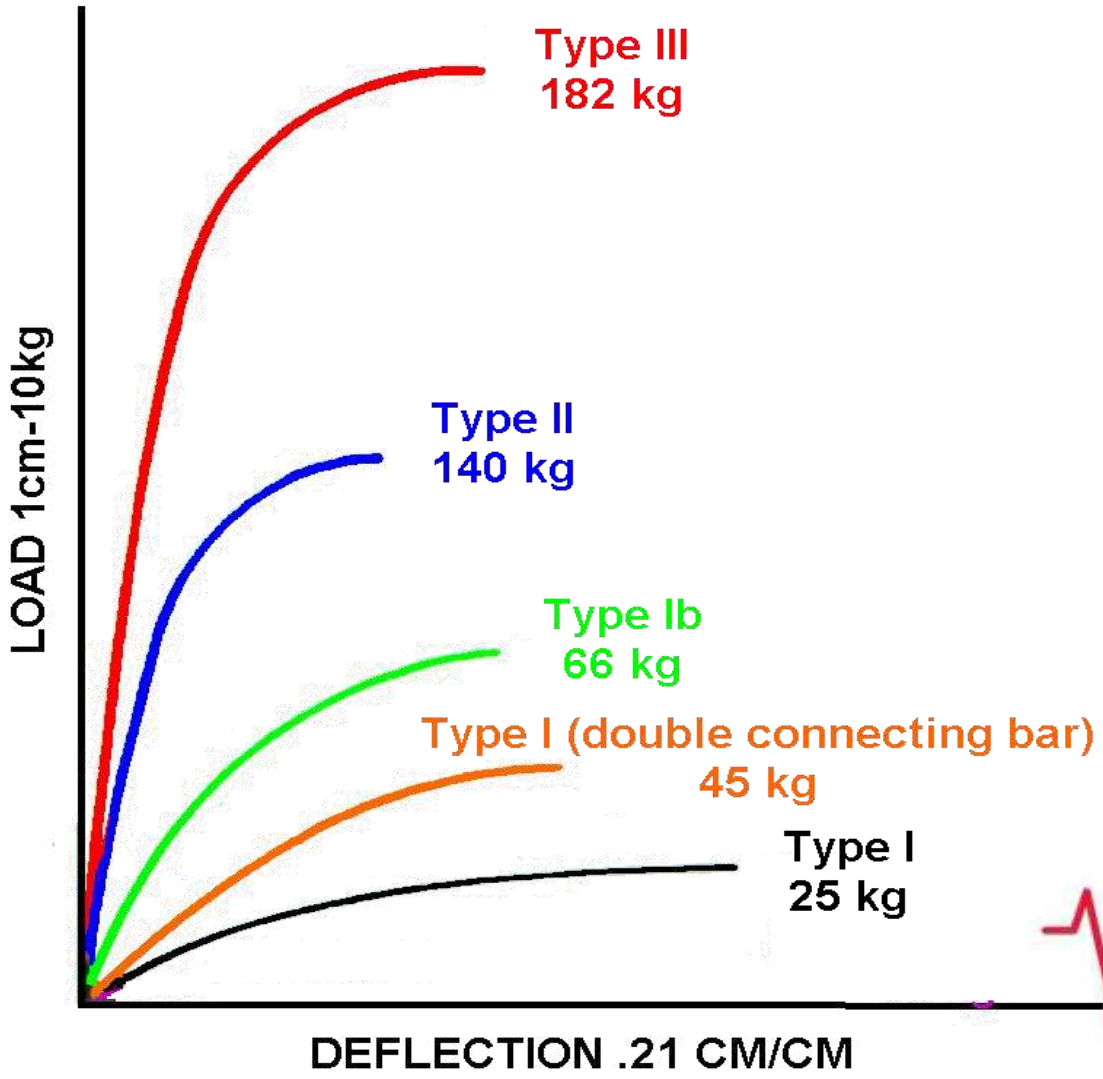

Increasing ESF rigidity

- Double bar / clamp
- Increase pin / bar diameter
  - Aim for 20-25% bone diameter for fixation pin
- Reduce bone-bar distance
- Pin distribution
  - >1cm from fracture site
  - Even spread across proximal and distal fragments
- Number of pins (up to 4 per fragment)

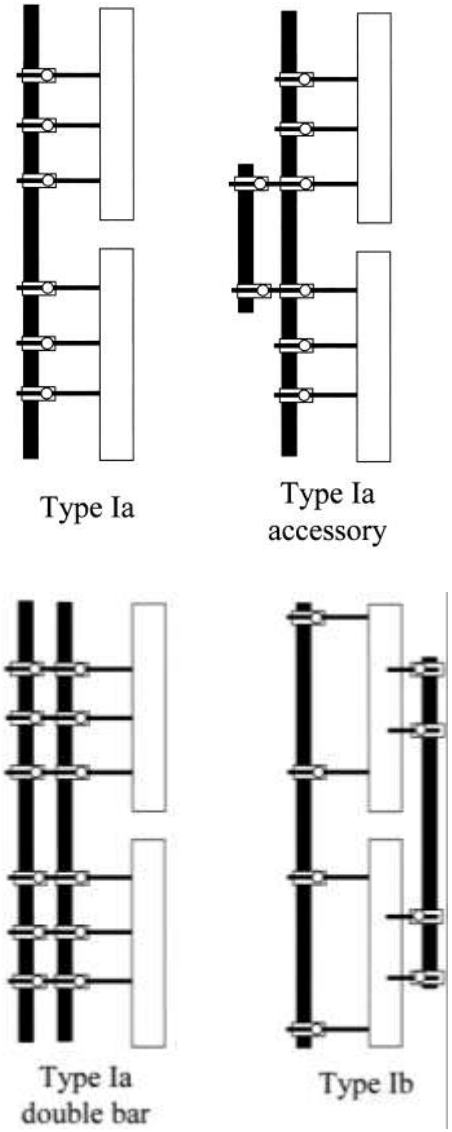

Increasing ESF rigidity

- Tie-in IM Pin

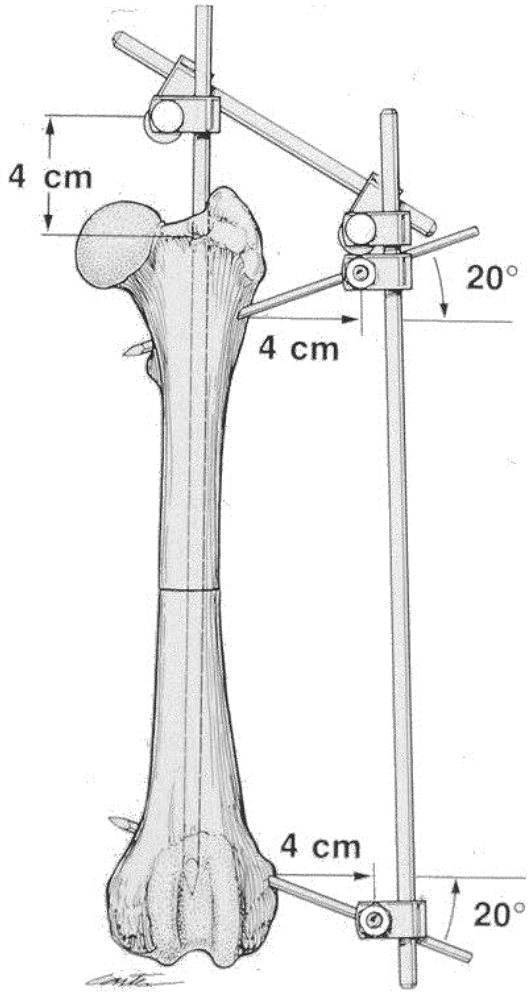

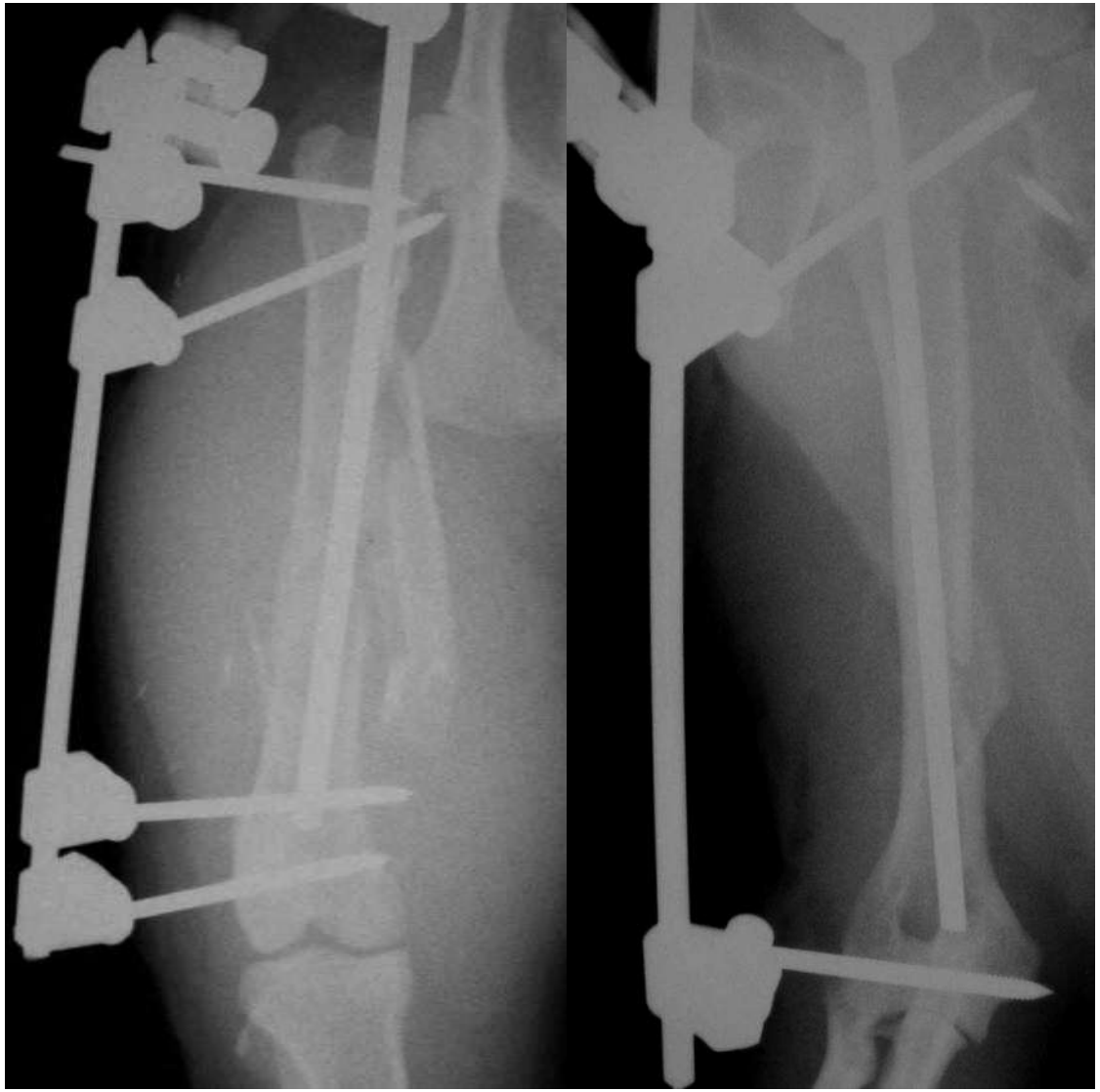

Increasing ESF rigidity

- Application of “struts” to join frame components

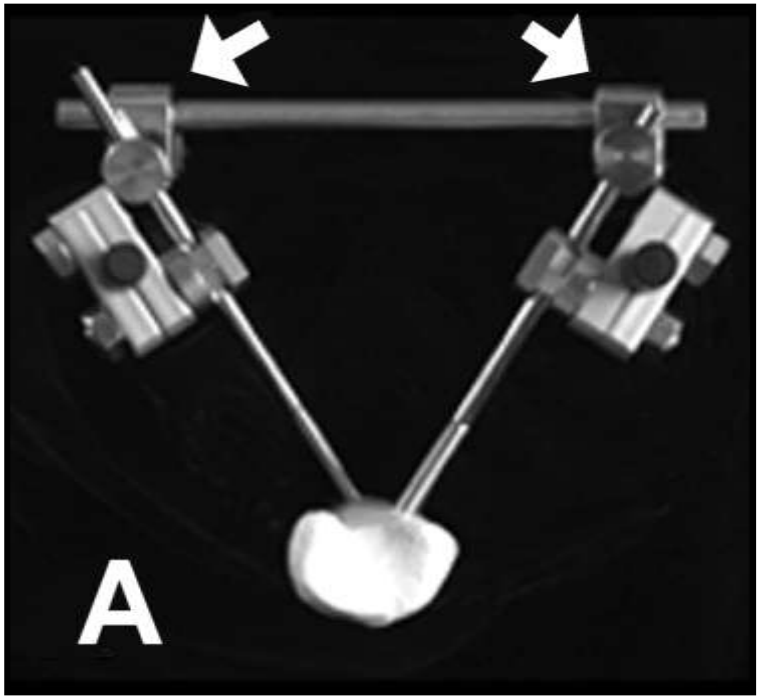

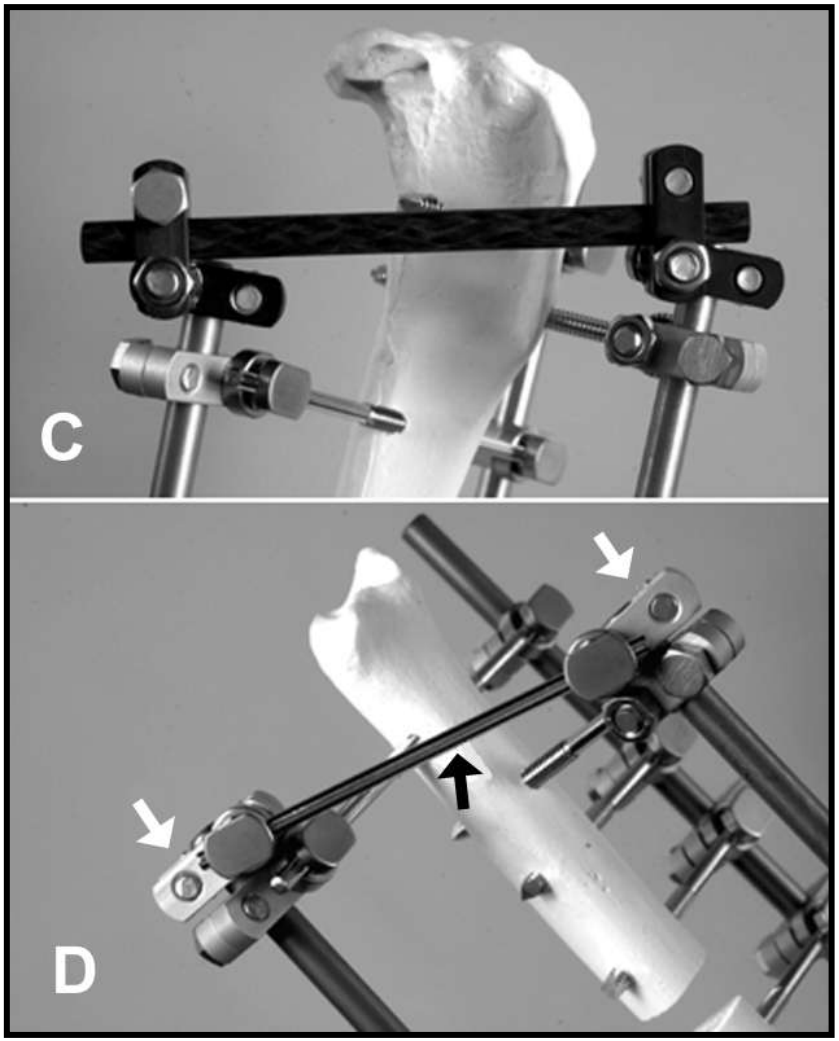

Special components

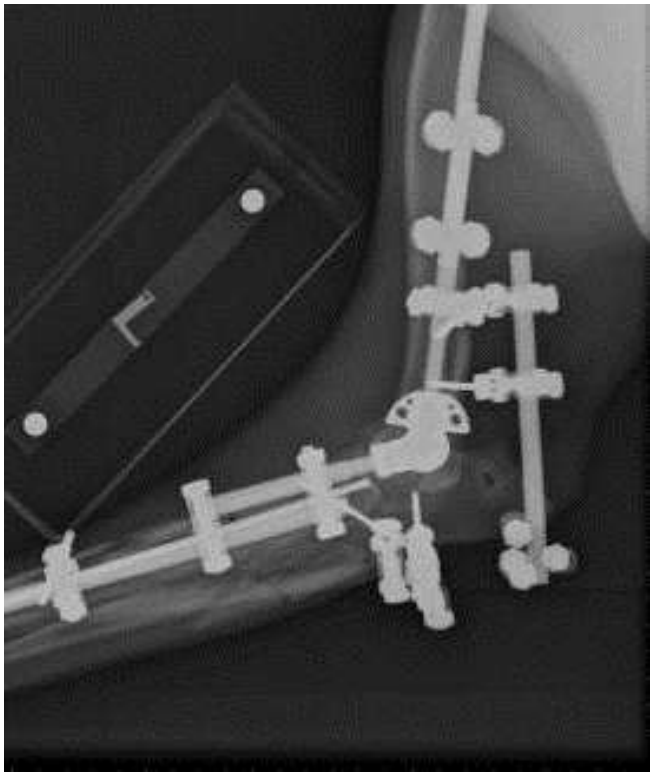

Fixation Pins

- Weakest link is the bone-pin interface

Fixation Pins: Design

<u>Positive Profile Pins</u>

- Superior stiffness and axial extraction characteristics (site dependent)
- Pre-drill (0.1mm <pin core diameter)
- Low insertion speed (<150rpm)

Fixation Pins: Design

Negative Profile Pins:

- Ellis Pins
- Thread-shaft interface is stress riser
- Stress riser effect mitigated if interface is positioned in medullary canal

Partially threaded Steinmann pin

Ellis pin

Fixation Pins: Design

Tapered thread run-out pins (IMEX “Duraface”)

- 55% stiffer than equivalent diameter +ve profile pins

Fixation Pins: Application

- Pre-drilling pilot hole →
  - ↓mechanical damage
  - ↓ heat generation

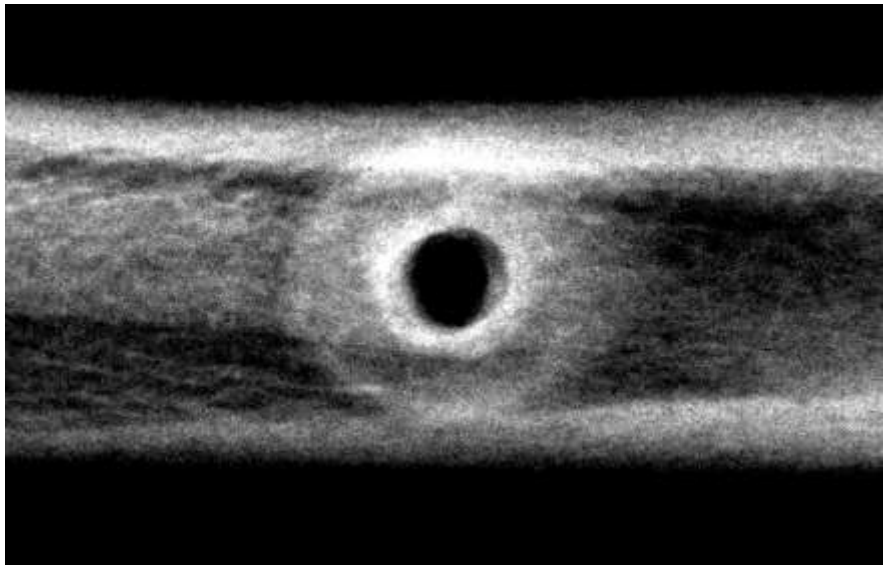

Ring sequestrum

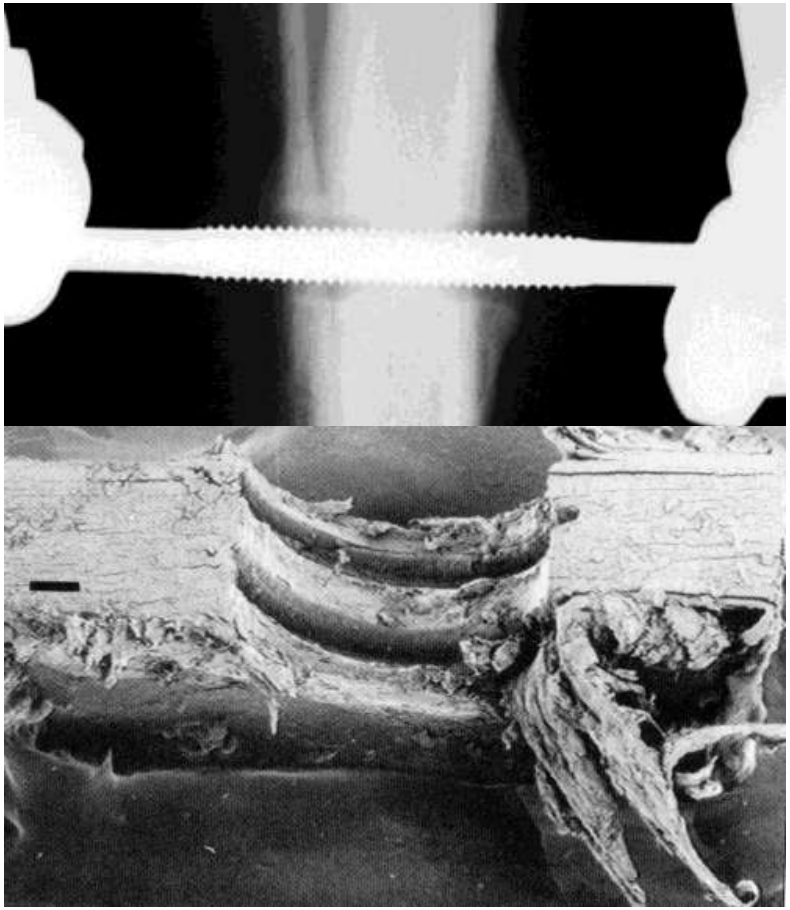

Bone necrosis occurs @ 56° for 10 secs

DRILL BIT



Twist channel in drill bit → escape of debris while drilling → minimizing frictional heat – <u>high RPM</u>

FIXATION PIN



No escape channel for debris – <u>low RPM</u>

Fixation Pins: Application

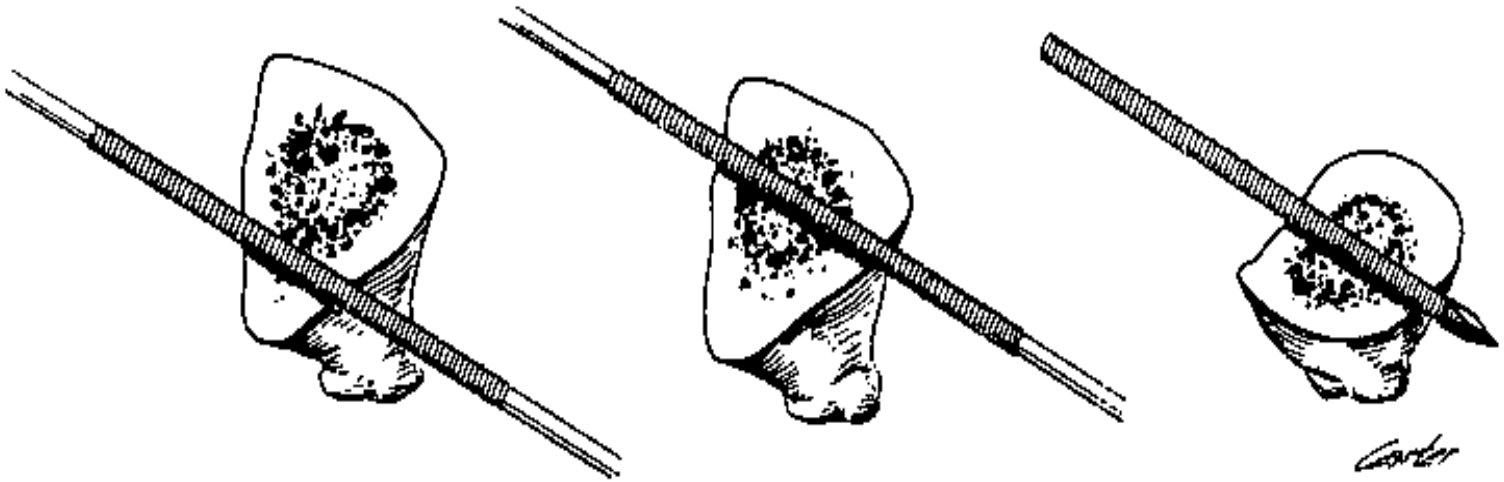

- Fixation pin < 30% bone diameter
- Beveled tip of half pins should completely penetrate far cortex

Fixation Pins: Application

- Small / stab incisions
- Not through traumatic / surgical wounds
- Space pins appropriately
- Distance bars / clamps from skin
  - Post-op swelling
  - Joint movement (esp elbow and hock)
- “Safe corridors”
  - Neurovascular bundles
  - Large muscle masses

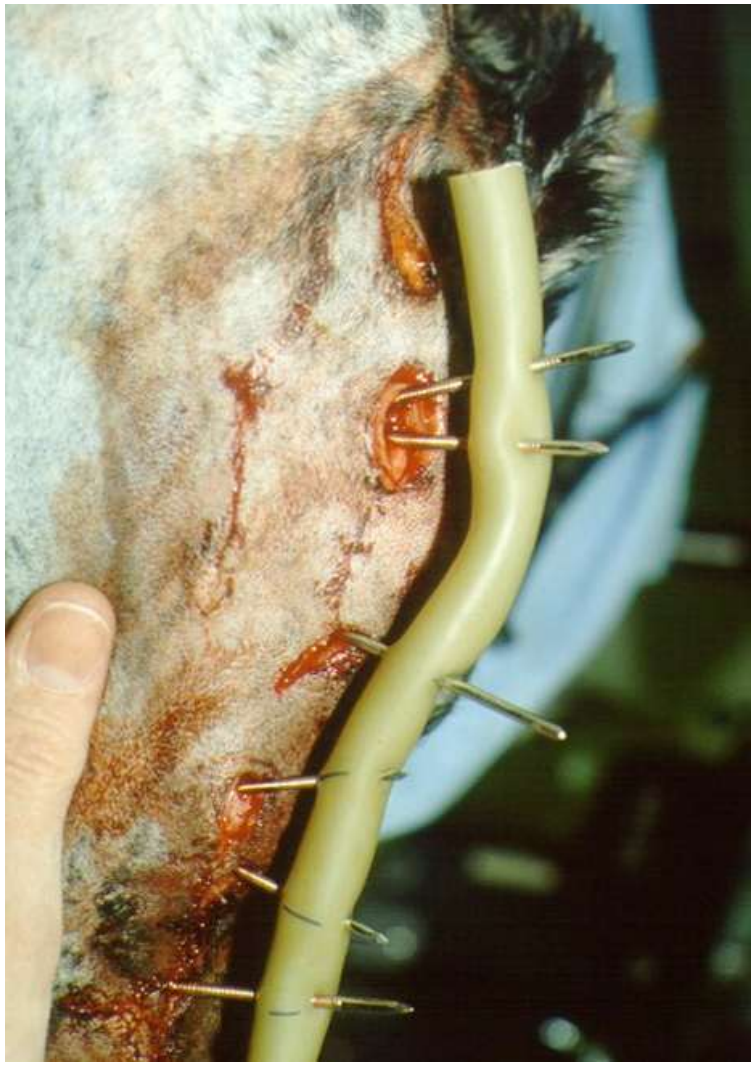

Circular / ring ESF

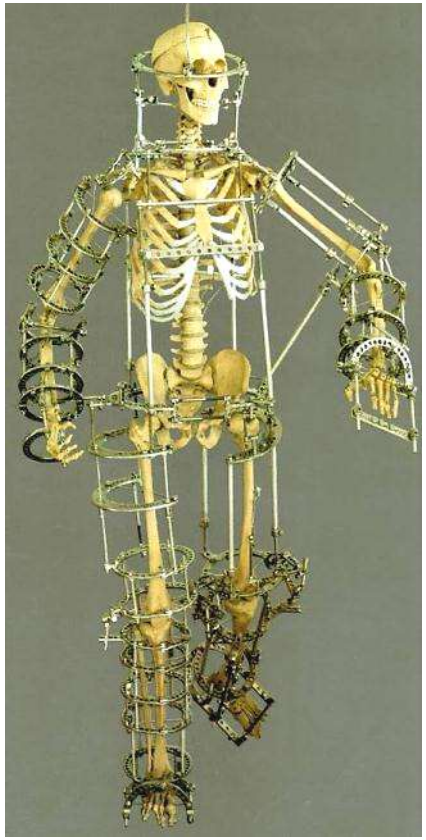

cESF

Gavriil A Ilizarov, MD

- Graduated from medical school in 1944
- Staff surgeon at Hospital for War Invalids, Western Siberia
- Faced with consequences (nonunion fractures, bone defects and osteomyelitis) of WWII

cESF

- Lack of facilities, equipment and antibiotics

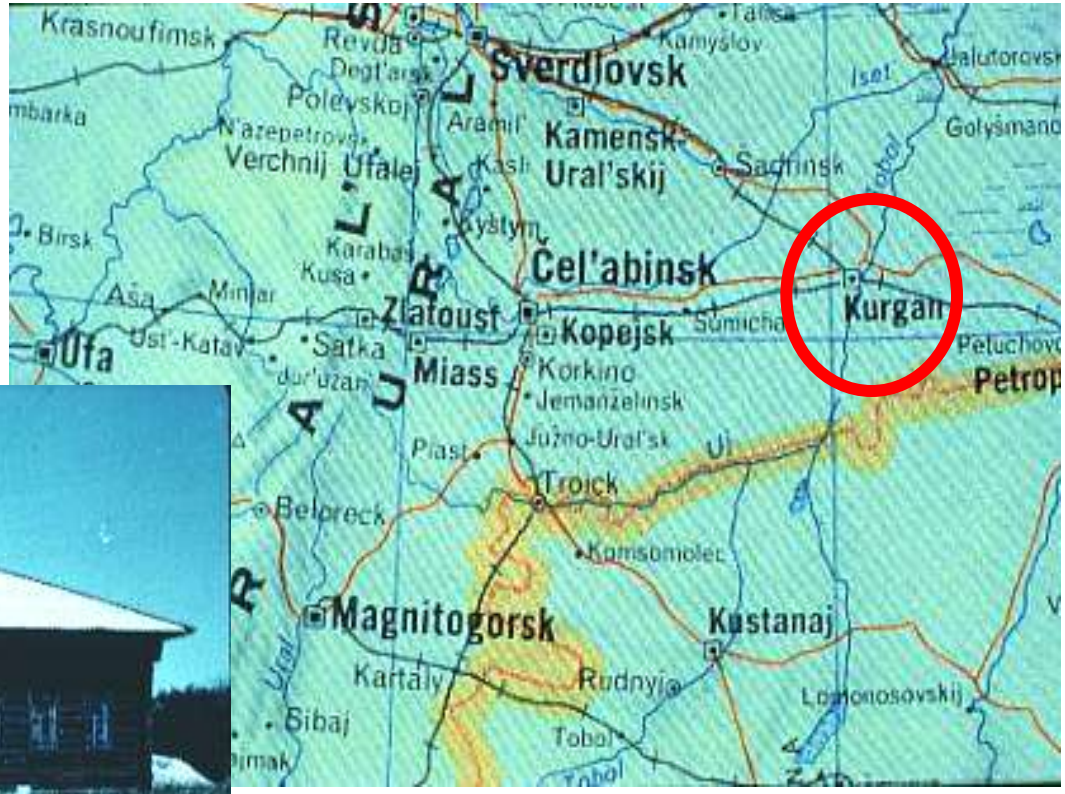

Vetsnow
Improving the lives of vets & pets

cESF

- Ilizarov Method revolutionized
  - limb lengthening
  - deformity correction
  - bone transport
  - soft tissue expansion
  - cranio-facial reconstruction
  - fracture management

cESF

- Small diameter fixation wires
- One wire either side of each ring
- Wires tensioned to improve stiffness (depending on ring / patient size)

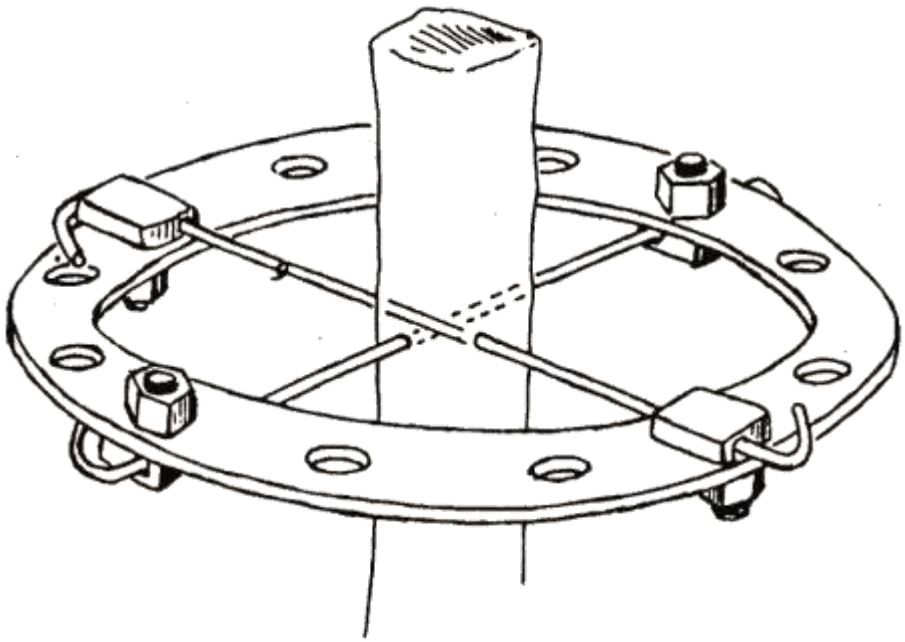

Fixation Elements: Wires

- 1.6 and 1.0mm diameter wires
- Single lip cutting point
- Stopper or olive wires



Wire placement

- Minimal soft tissue penetration
- Perpendicular wire placement
- Wires flat against rings
  - Above
  - Below
  - Washer spacers / bolts / posts
- Wire tensioning



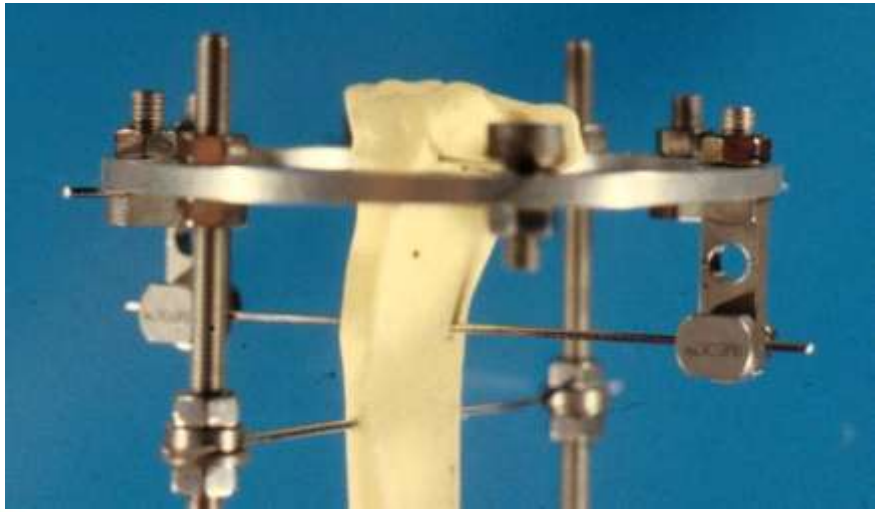

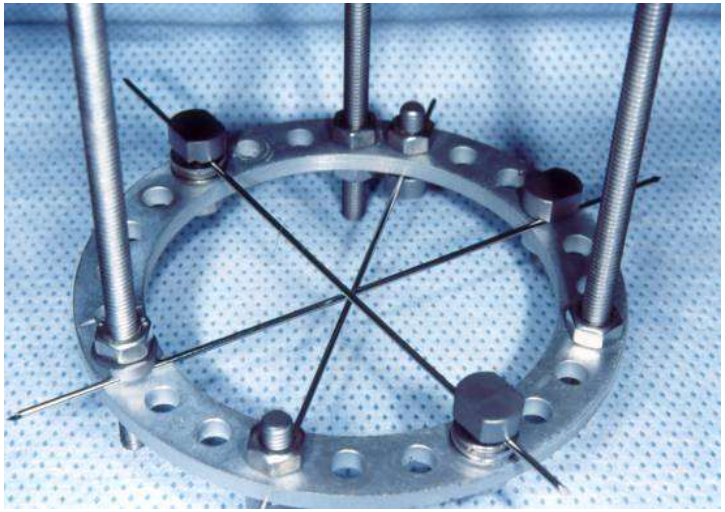

Supporting Elements: Rings

- High strength tempered aluminum alloy
- Full, 5/8, 1/3 ring arches
- Assorted other shapes



Supporting Elements: Rings

Ring diameter is single most important variable affecting biomechanics of cESF

- Selection based on patient dimensions
- Minimum ring diameter
  - Must leave 1-2cm clearance between soft tissues & rings

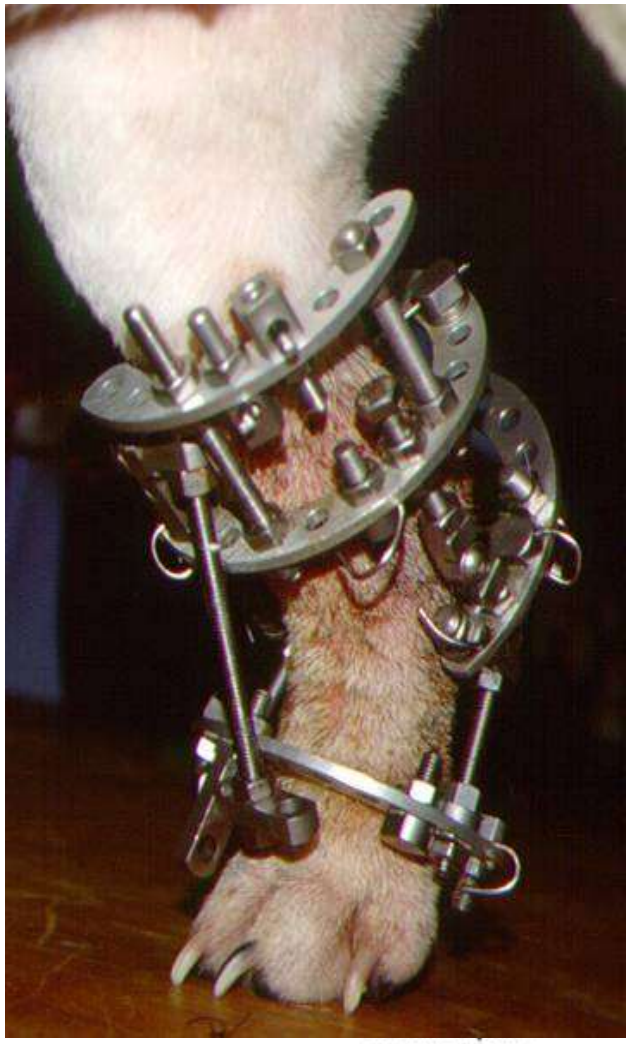

Connecting Elements

- Linear motors
- Threaded rods



Assembly Elements

- Fixation bolts
- Washers
- Hinges

cESF advantages

- Small fragment stabilisation
  - Juxta-articular fractures
- Versatile
- Self-dynamising
  - Controlled axial micromotion
  - Excellent resistance to bending and rotation forces
- Minimal soft tissue disruption
  - Especially if applied closed

Fracture Management

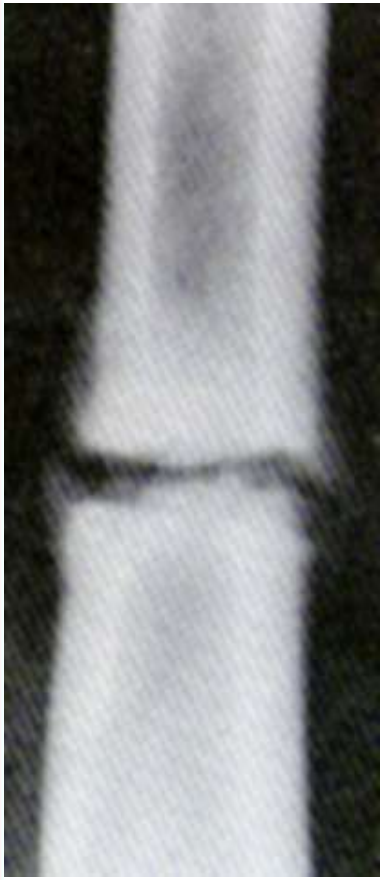

Rigid

Micromotion

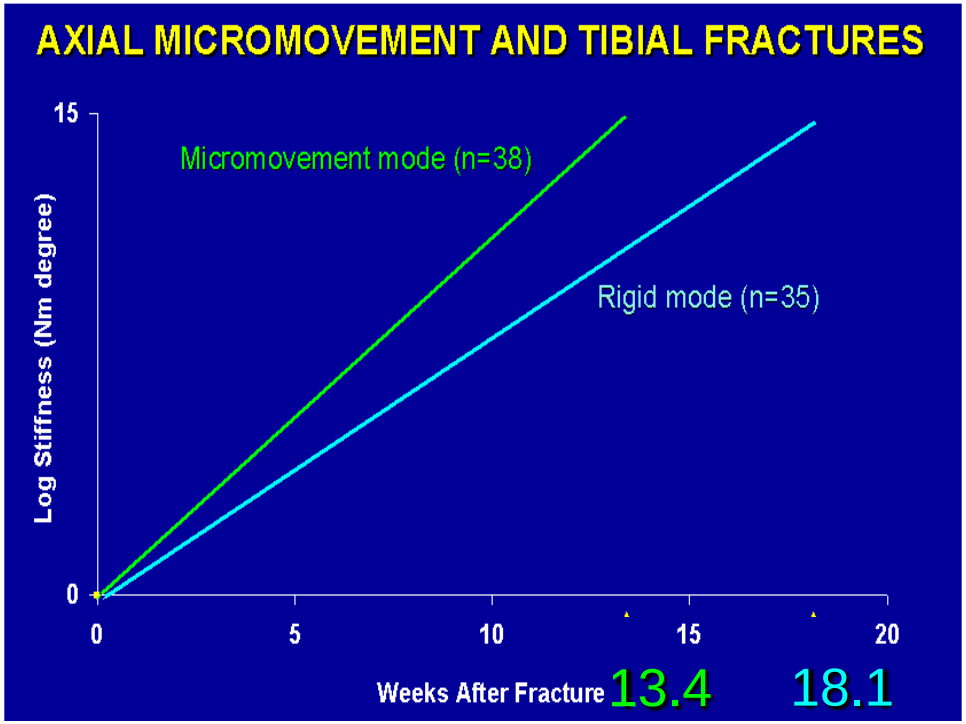

cESF application

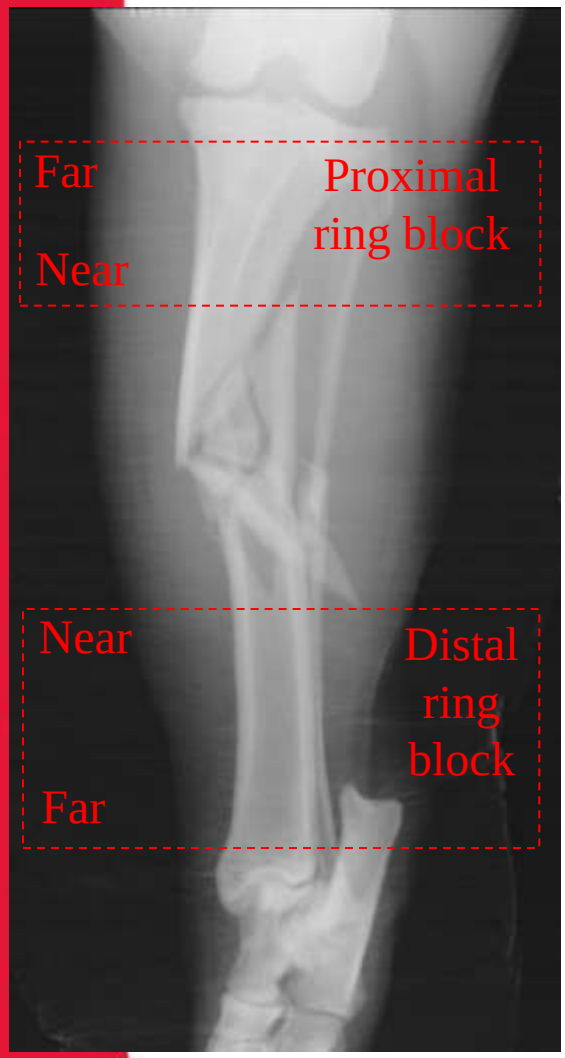

- <u>"Far-near-near-far" fixation</u>
- Two ring blocks separated by linear motors

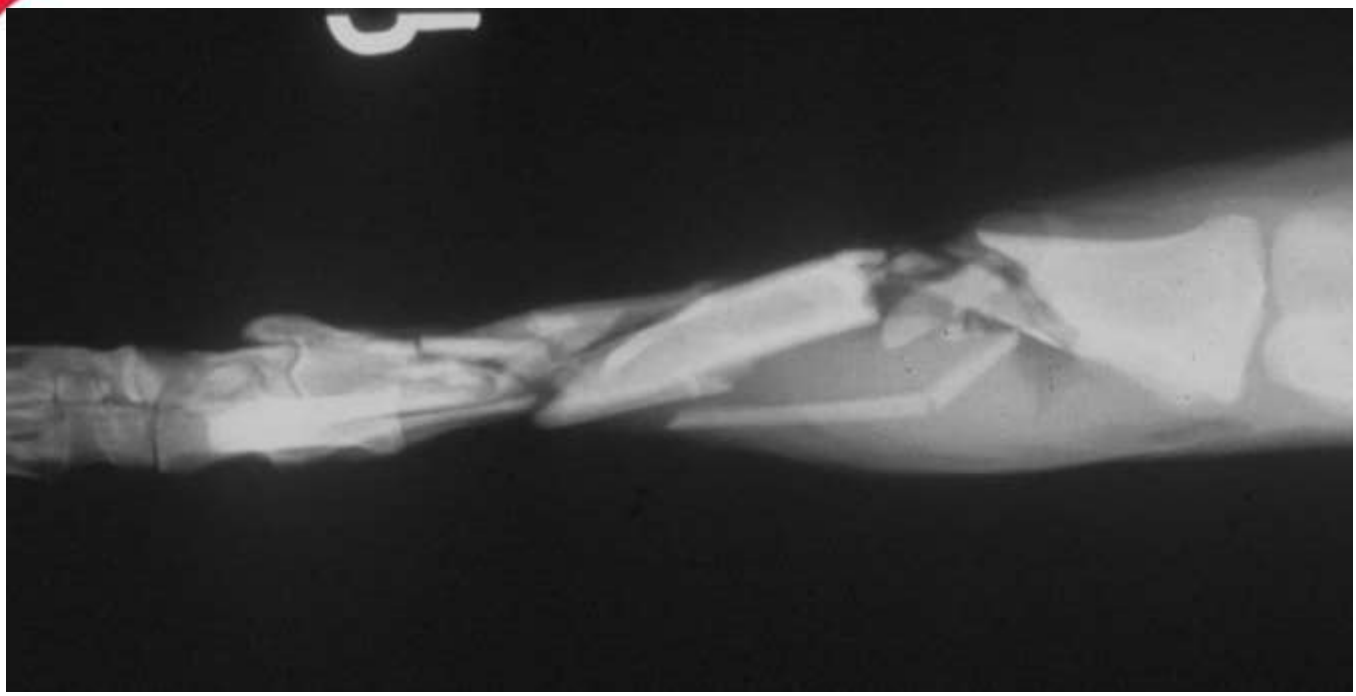

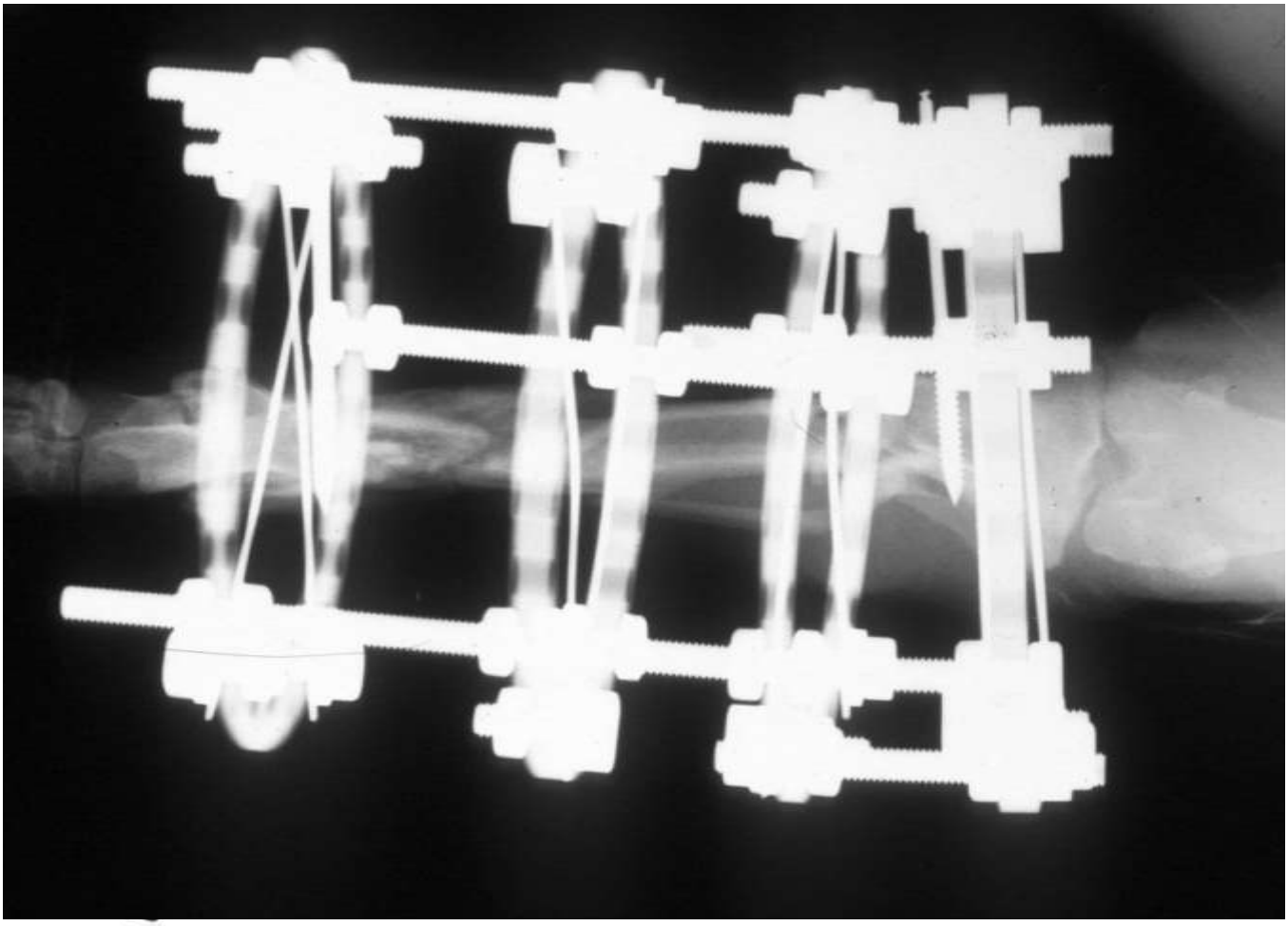

Post-op management

- Minimize skin-pin movement
- Prevent self-trauma from wire tips / sharp ends
- Radiography <q6-8 weeks
- Periodic checking apparatus tightness

Distraction osteogenesis

- Law of Tension Stress
  - –slow steady tension stimulates cellular proliferation
  - –terminates when cells occupy their genetic space constraints
- Abbott 1939
- Ilizarov 1954



Distraction osteogenesis

Intramembranous bone formation

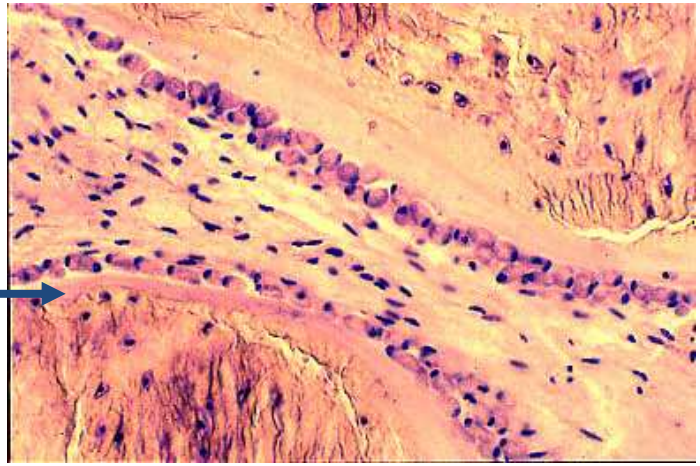

Endochondral bone formation

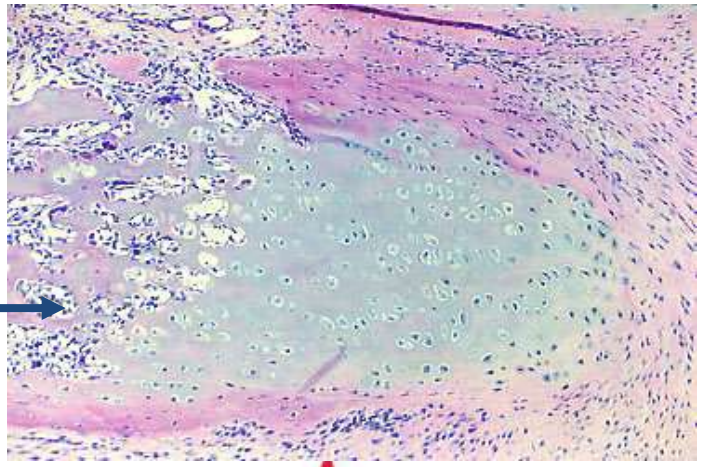

Similarities with fracture healing & embryonic bone development

Vetsnow
Improving the lives of vets & pets

Distraction osteogenesis



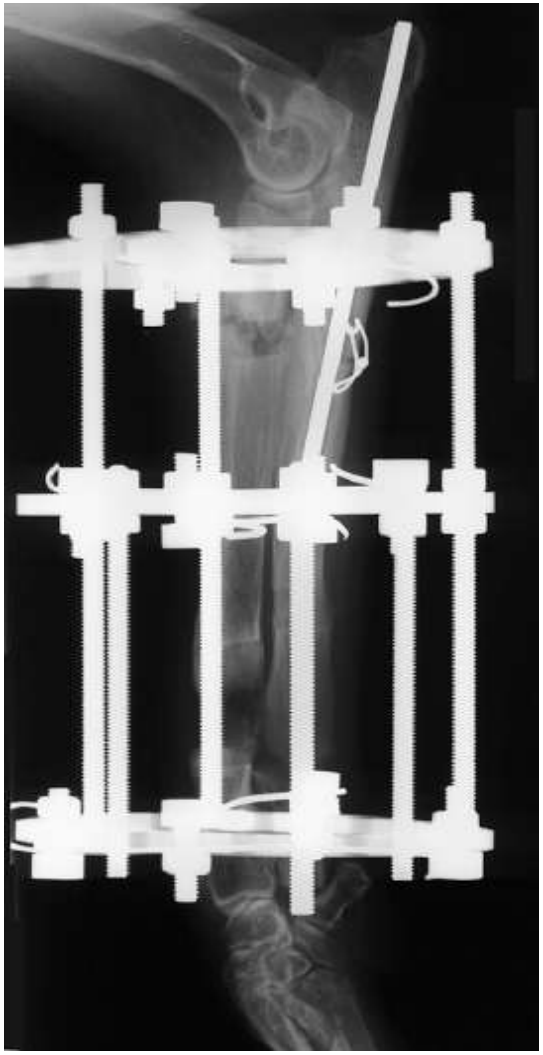

Bone transport

- Large bone defects
- Segment of bone is transported
  - –regenerate bone forms in its wake

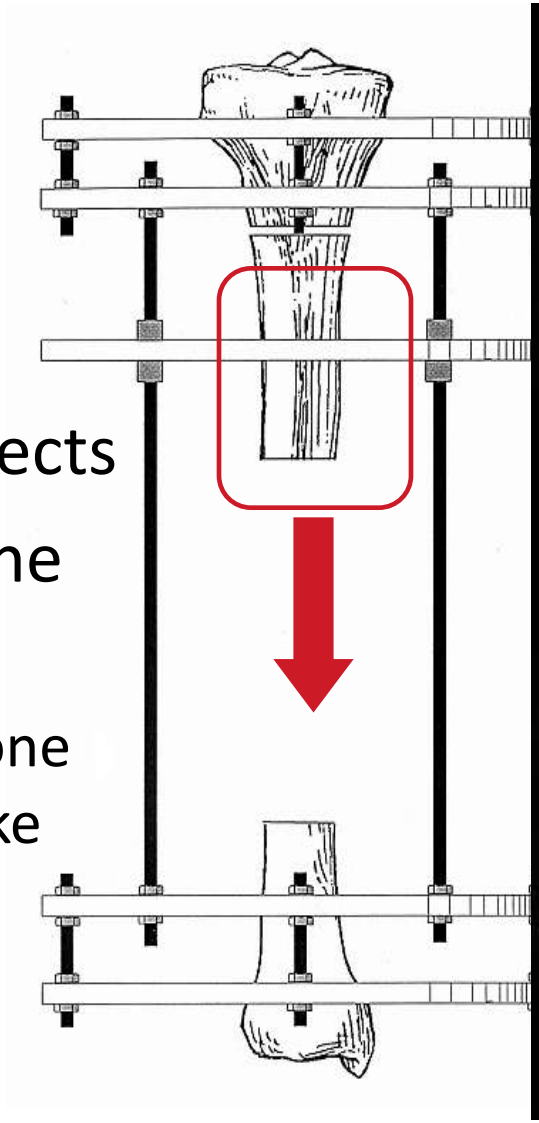

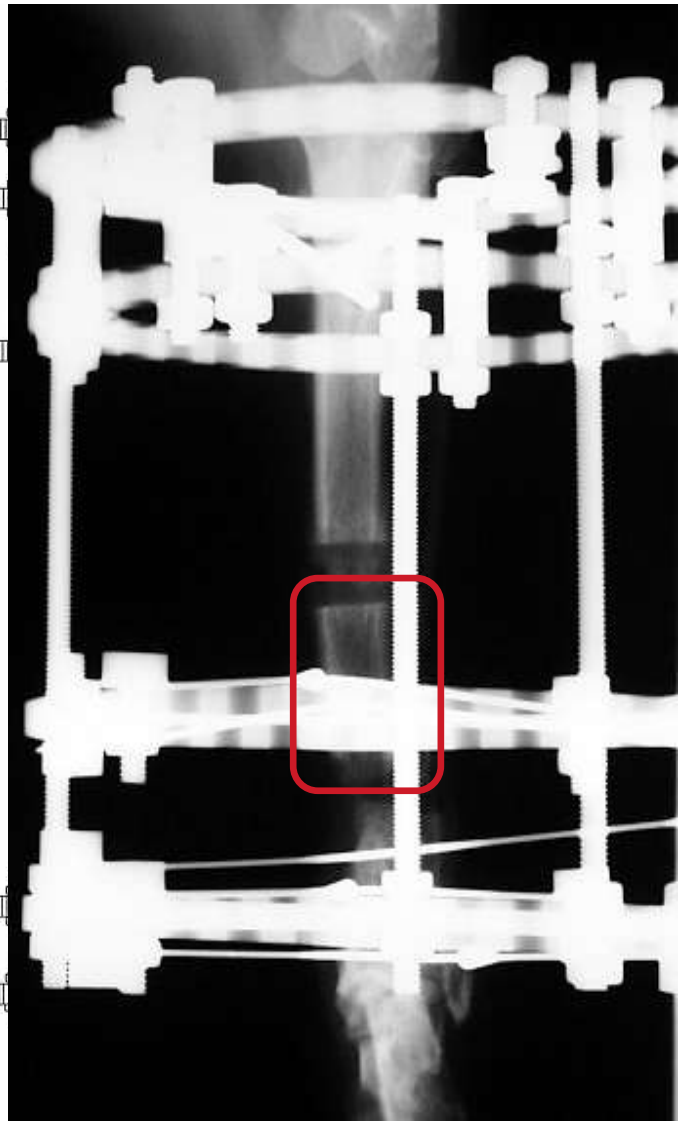

Hybrid ESF

Hybrid ESF

- Combines circular and linear components
- Uses threaded pins & transfixation wires

Hybrid ESF

Advantages:

- Quicker / simpler to apply
- Increased versatility
- Anatomical sites where full rings impractical
  - Femur
  - Humerus
  - Near joints

Disadvantage:

- Lose some benefits of axial micromotion from cESF (depending on construct)

Linear-Circular Hybrid Constructs

1A

1B

i/m pin tie-in

hESF application

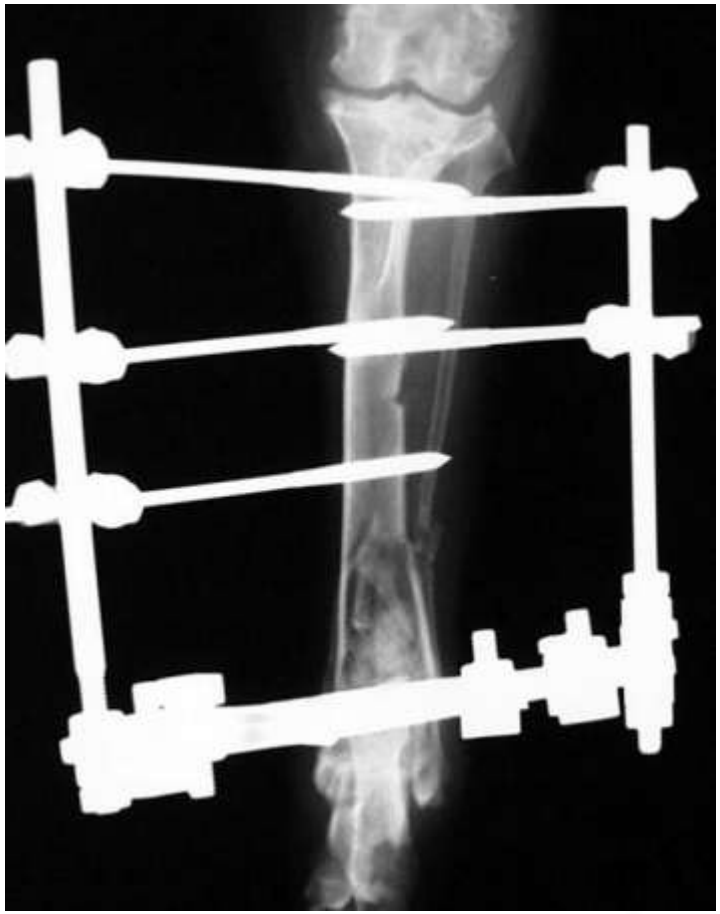

Acrylic / freeform ESF

Acrylic / epoxy resin ESF

Mix PMMA powder / solvent – fill tubing in semi-liquid phase prior to curing

Acrylic ESF: Advantages

- Pins any diameter
- Pins in almost any orientation
- Largely radiolucent
- Minimal distance between connecting column and bone
- Lightweight
- Limited inventory
- Cheap

Acrylic ESF: Disadvantages

- Difficult to maintain reduction if used for primary fixation
- Heat during polymerization (curing)
- Fumes are noxious, toxic and teratogenic
- Difficult to make adjustments
- Technical errors (bubbles, gaps, etc.)

“Pinless” ESF

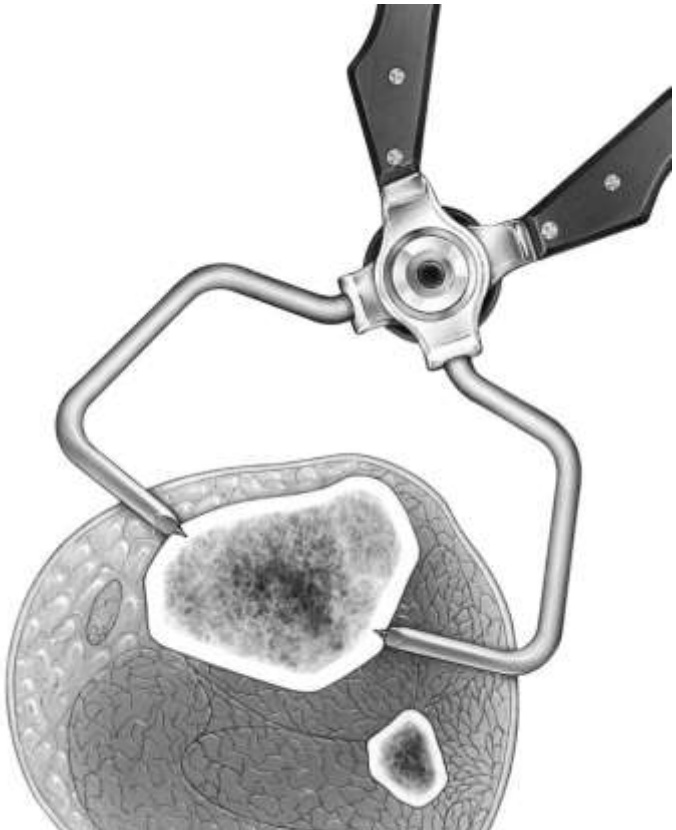

Extreme biologic ESF

- Pinless ESF – does not penetrate periosteum – minimal vascular compromise or potential for tracking infection
- Current system (Synthes) too large for small animal applications
- [Reported for mandibular fractures of cattle]

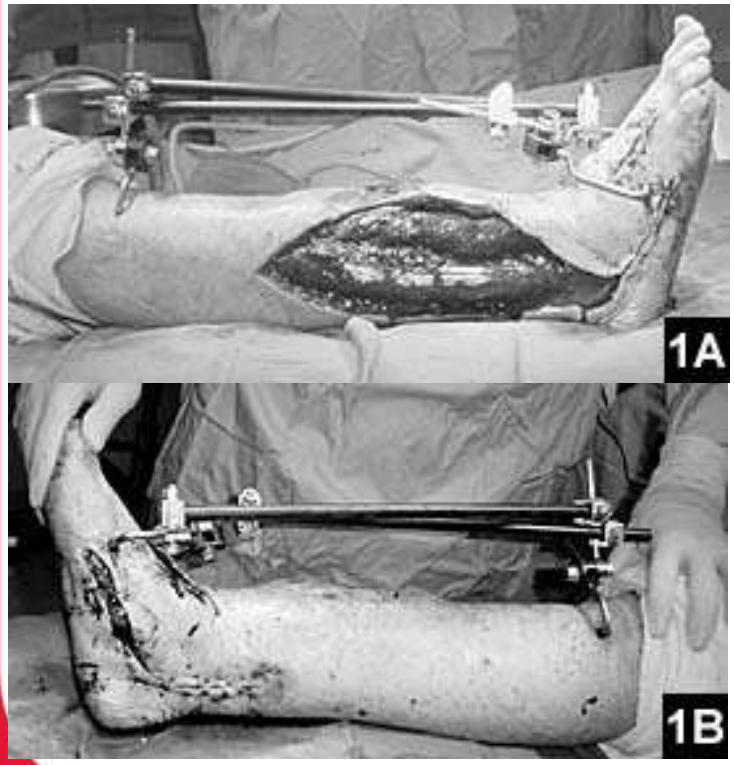

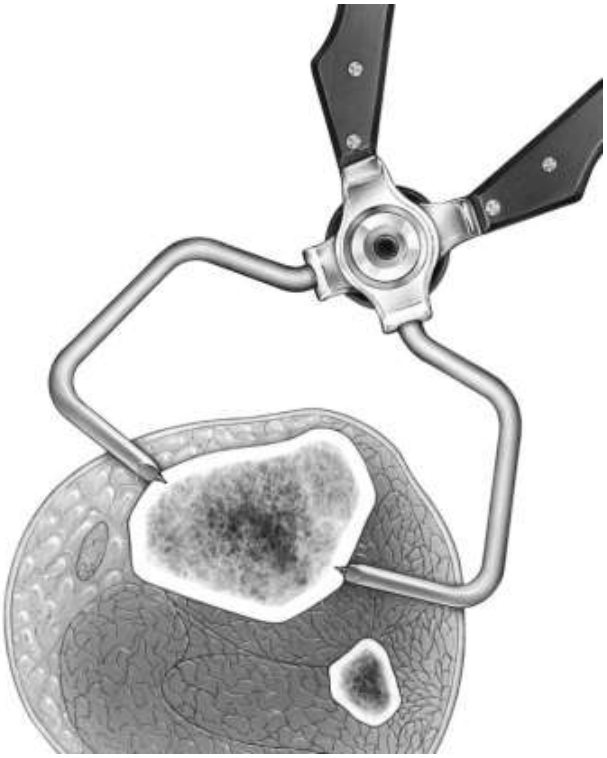

ESF application and management

A few key points

Carpentry vs gardening

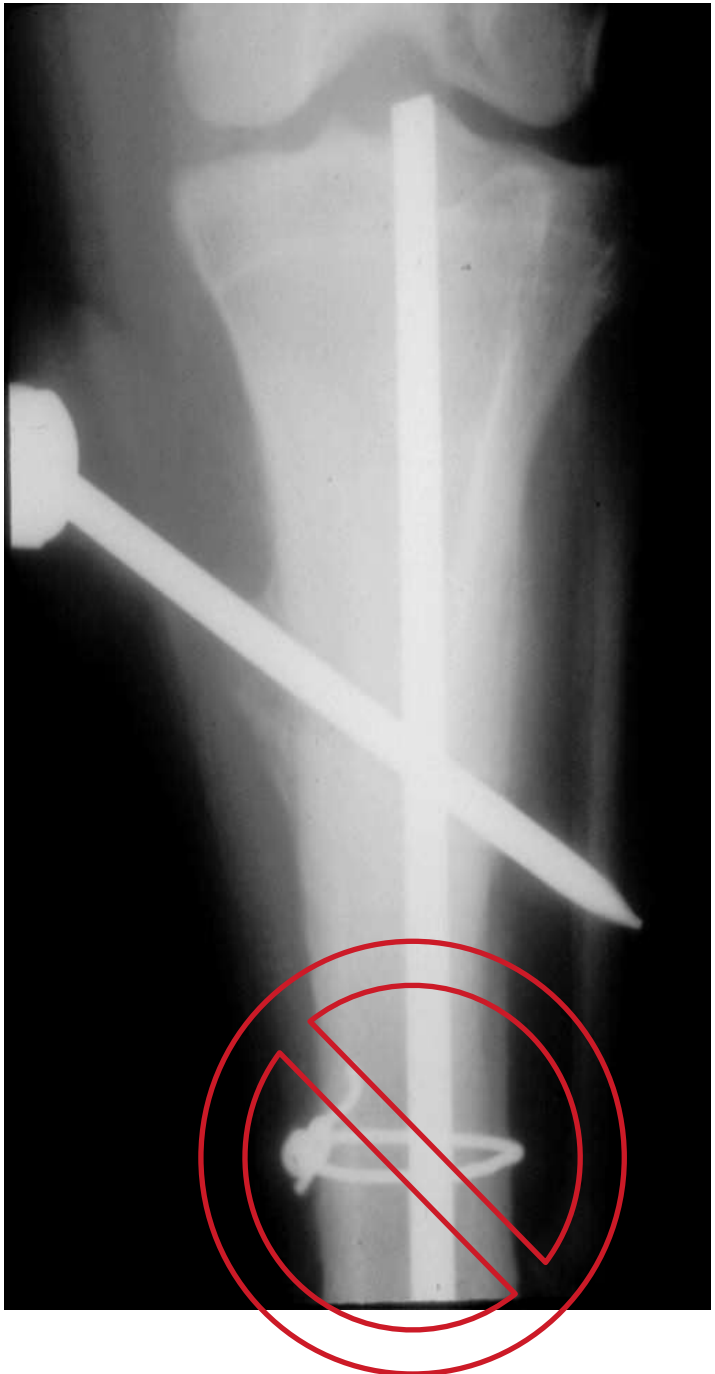

ESF Application

- Hanging limb prep?
- Fluoroscopy?
- Proximal and distal pins inserted first to re-establish limb axis and length

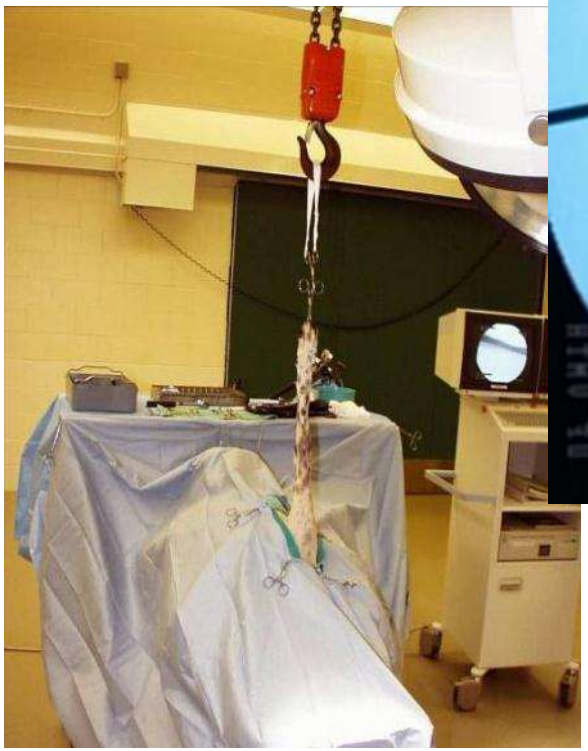

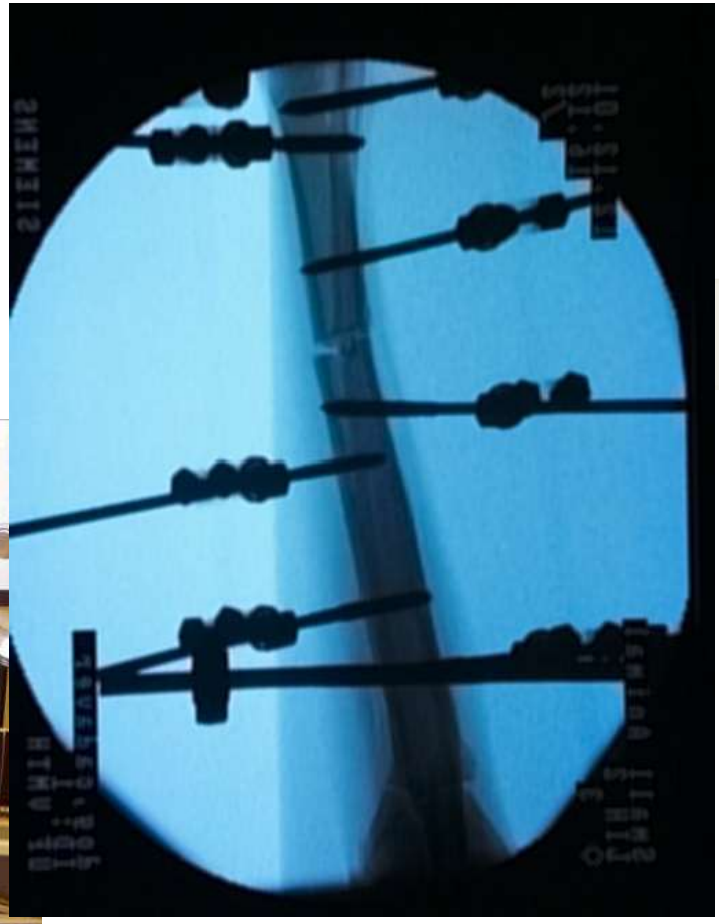

Destabilization

- 6w typically recommended
- Better to remove frame components than fixation pins
  - Destabilization <4 weeks:
    - ↑ callus, ↓mechanical strength
  - Destabilization at 6 weeks:
    - no ↑ callus, but ↑ mechanical strength
  - Destabilization at 12 weeks:
    - no ↑ callus or mechanical strength

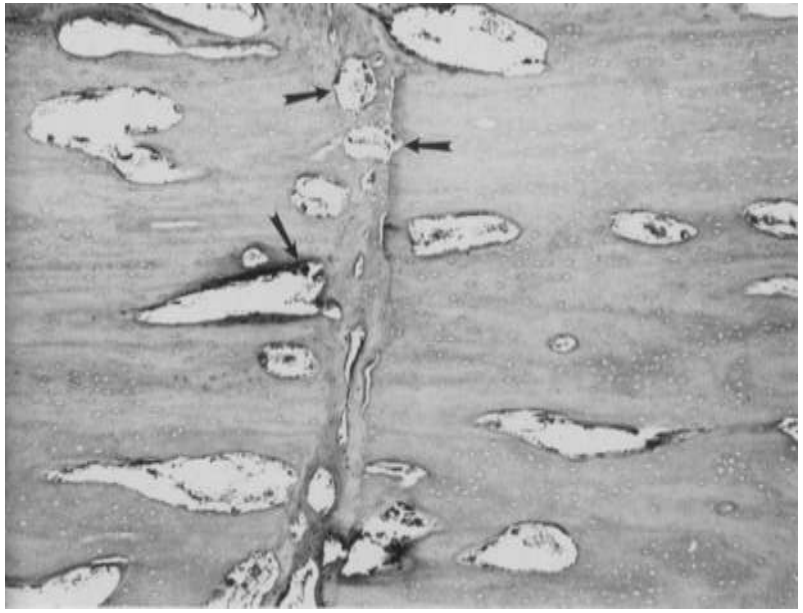

Aftercare

- Bandaging
- Cleaning???
- Antibiotics???

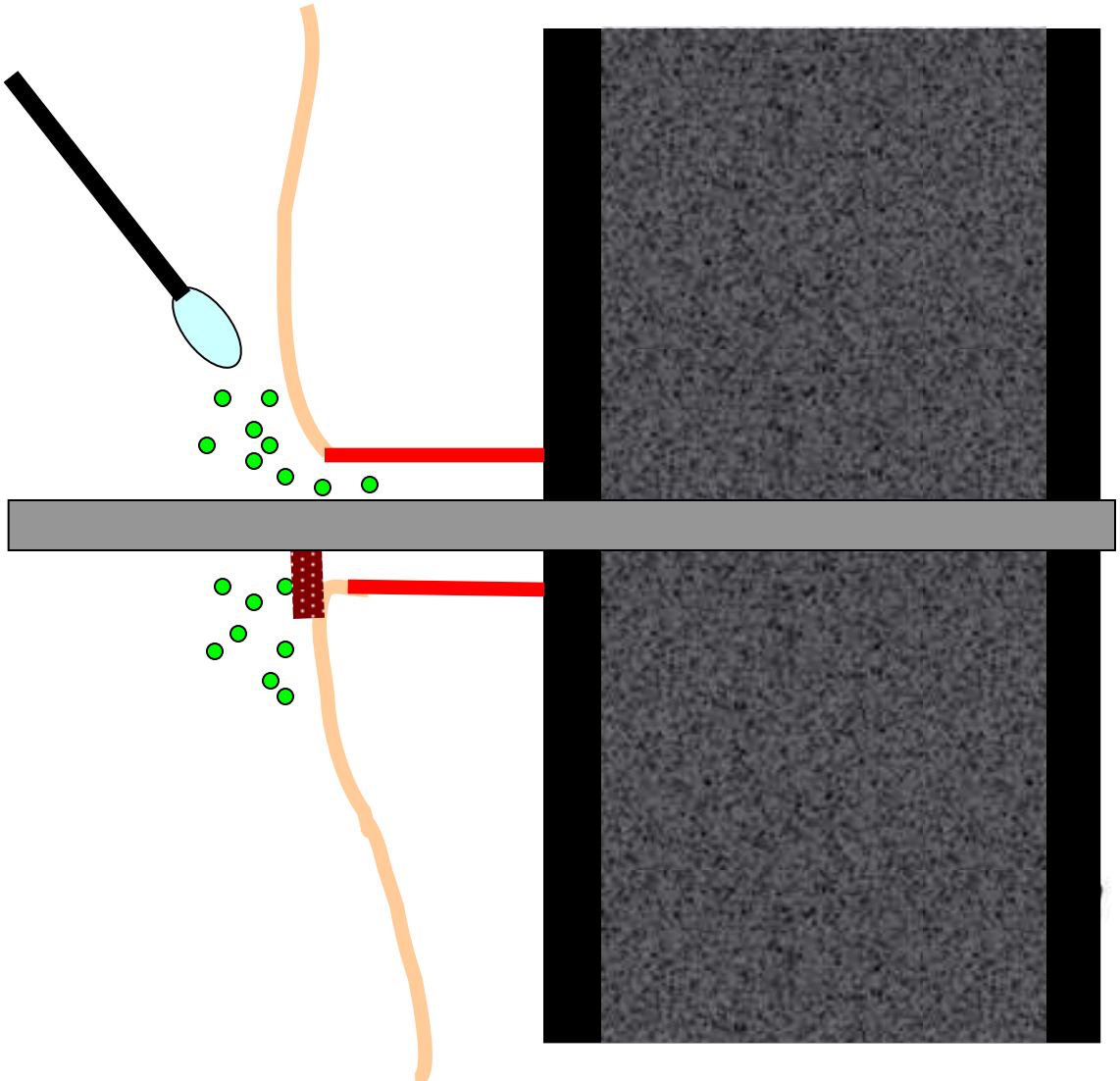

Pin tract discharge

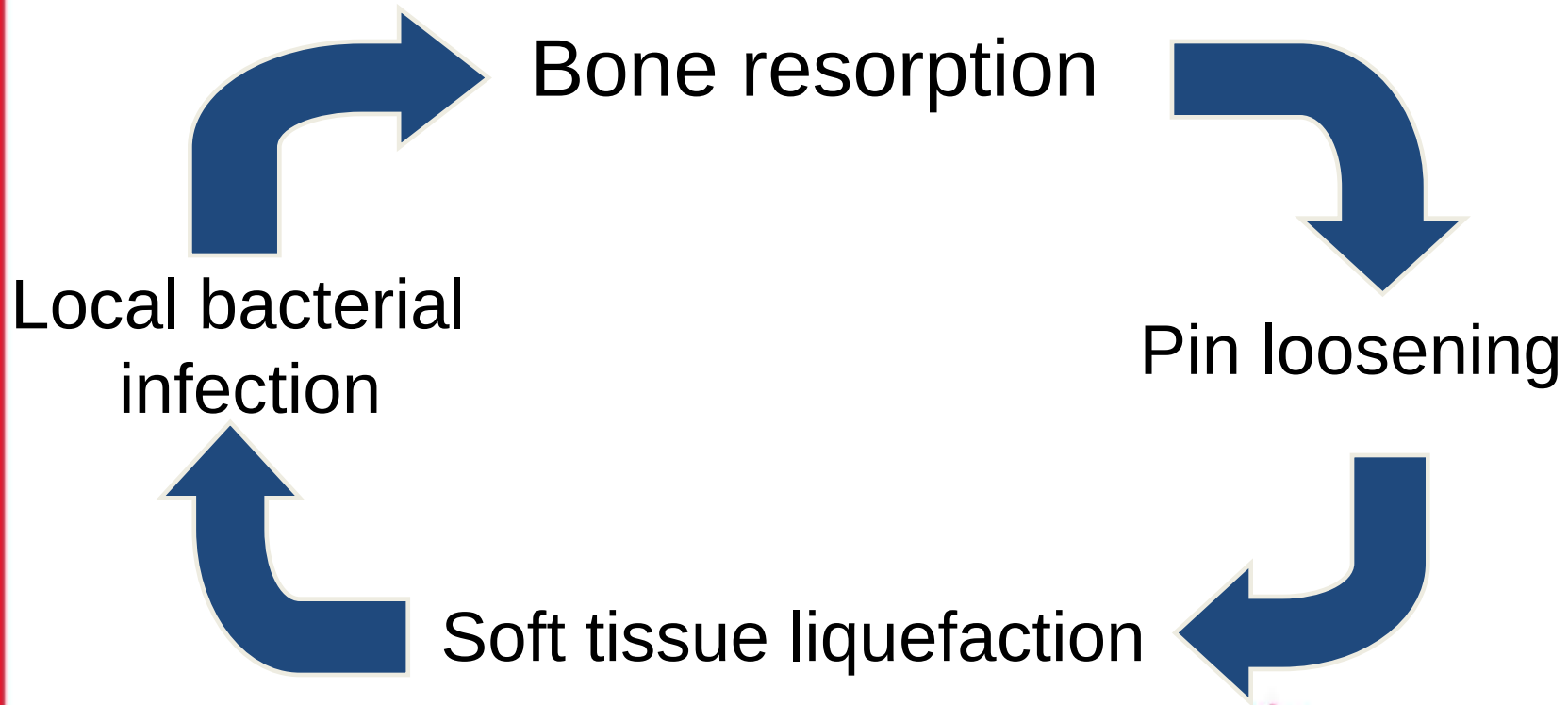

Case selection

- Will fracture healing occur before the ESF fails?
  - All ESFs will have some complication if left in situ long enough
  - Fracture biology
  - Patient signalment
- Is ESF mechanically appropriate?
- Additional considerations (owner factors, lifestyle, fixator management, personal experience / preference)

Internal fixation often more appropriate

How do we choose ESF configuration?

- BIOMECHANICS and BIOLOGY
- Fracture type, location, configuration
- Patient age, weight, and activity
- Other injuries
- Surgeon skill, experience, and equipment

Plan

- Quick review of bone biology
  - Direct healing
  - Indirect healing
- External Skeletal Fixation
  - Major types, configurations and mechanics
  - Application techniques
- Examples of different applications

Long bone fractures

Comminuted humeral fracture - ESF

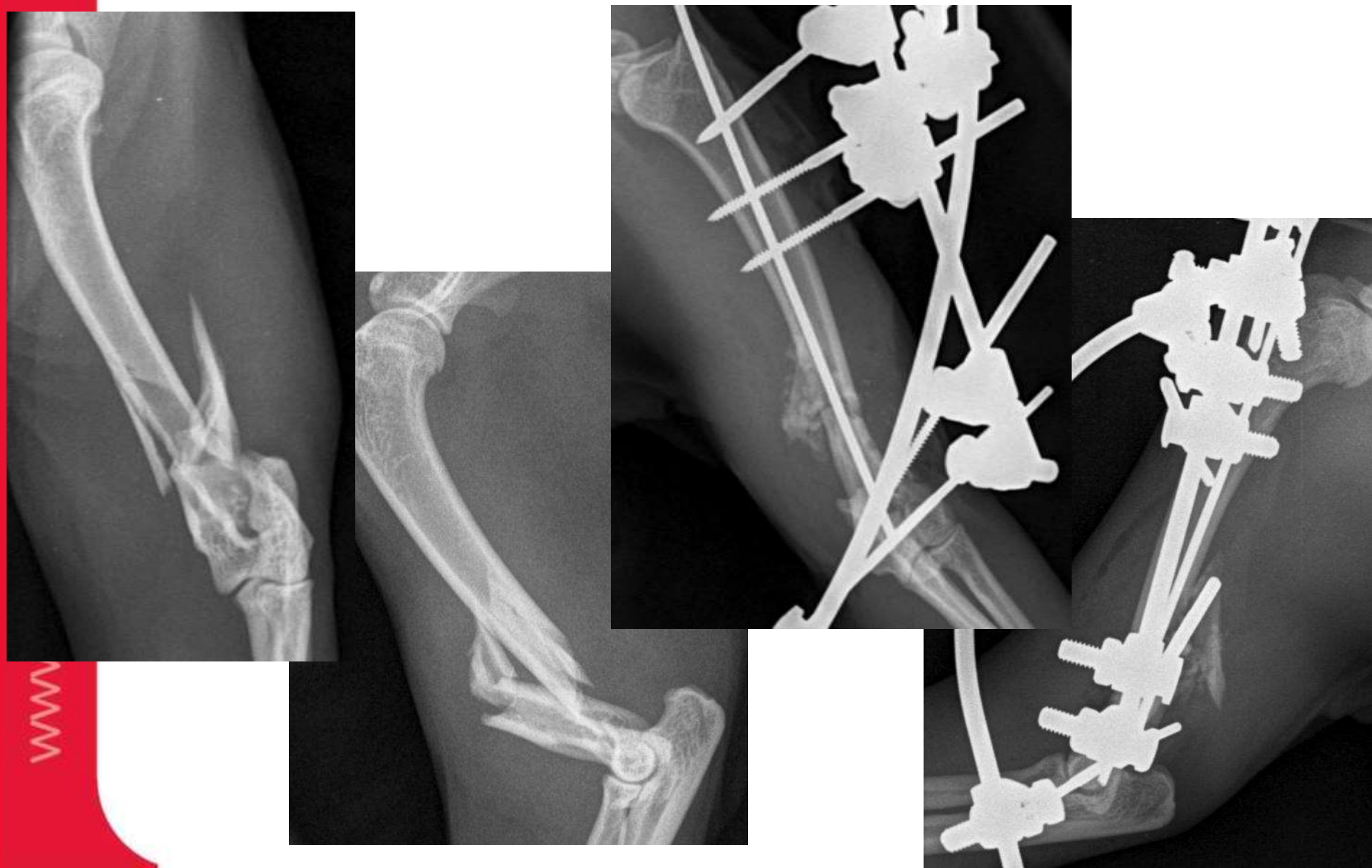

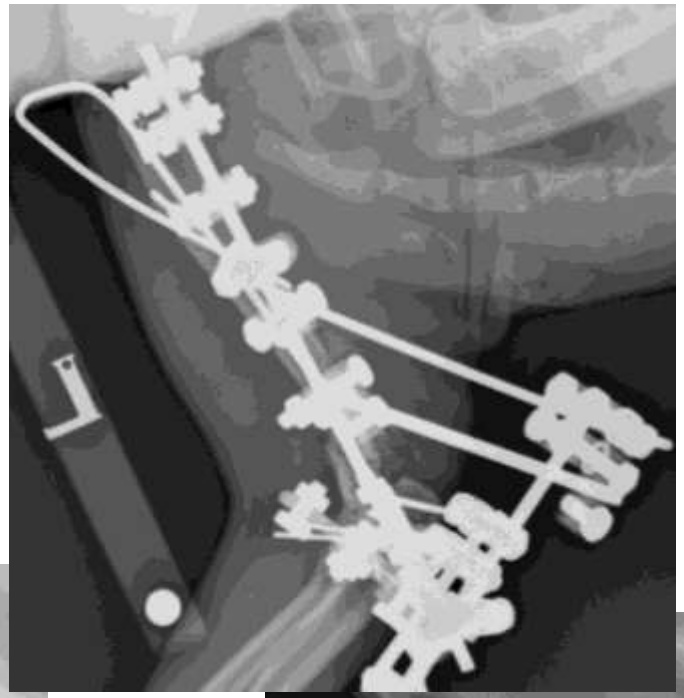

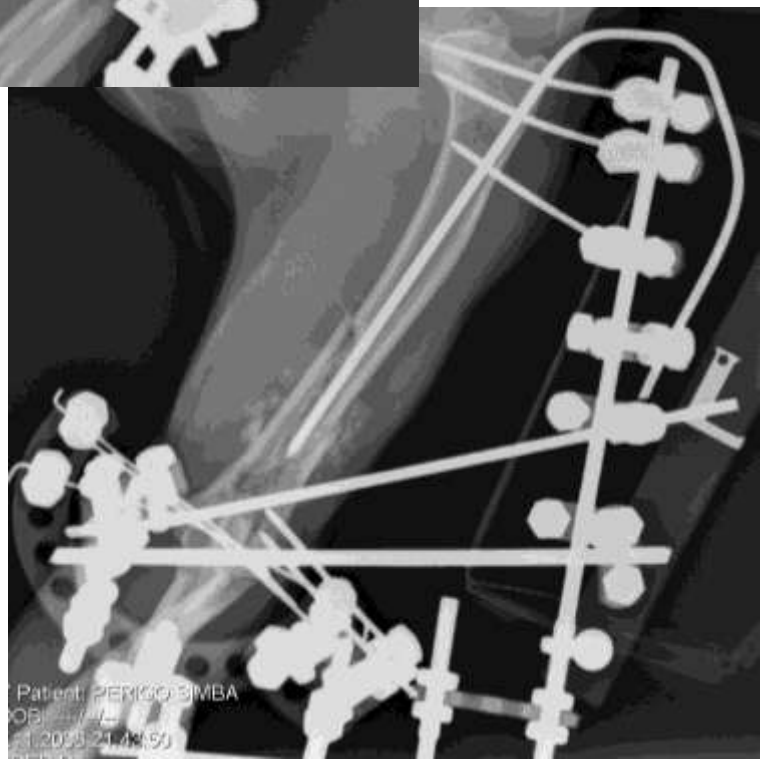

Radius / ulna

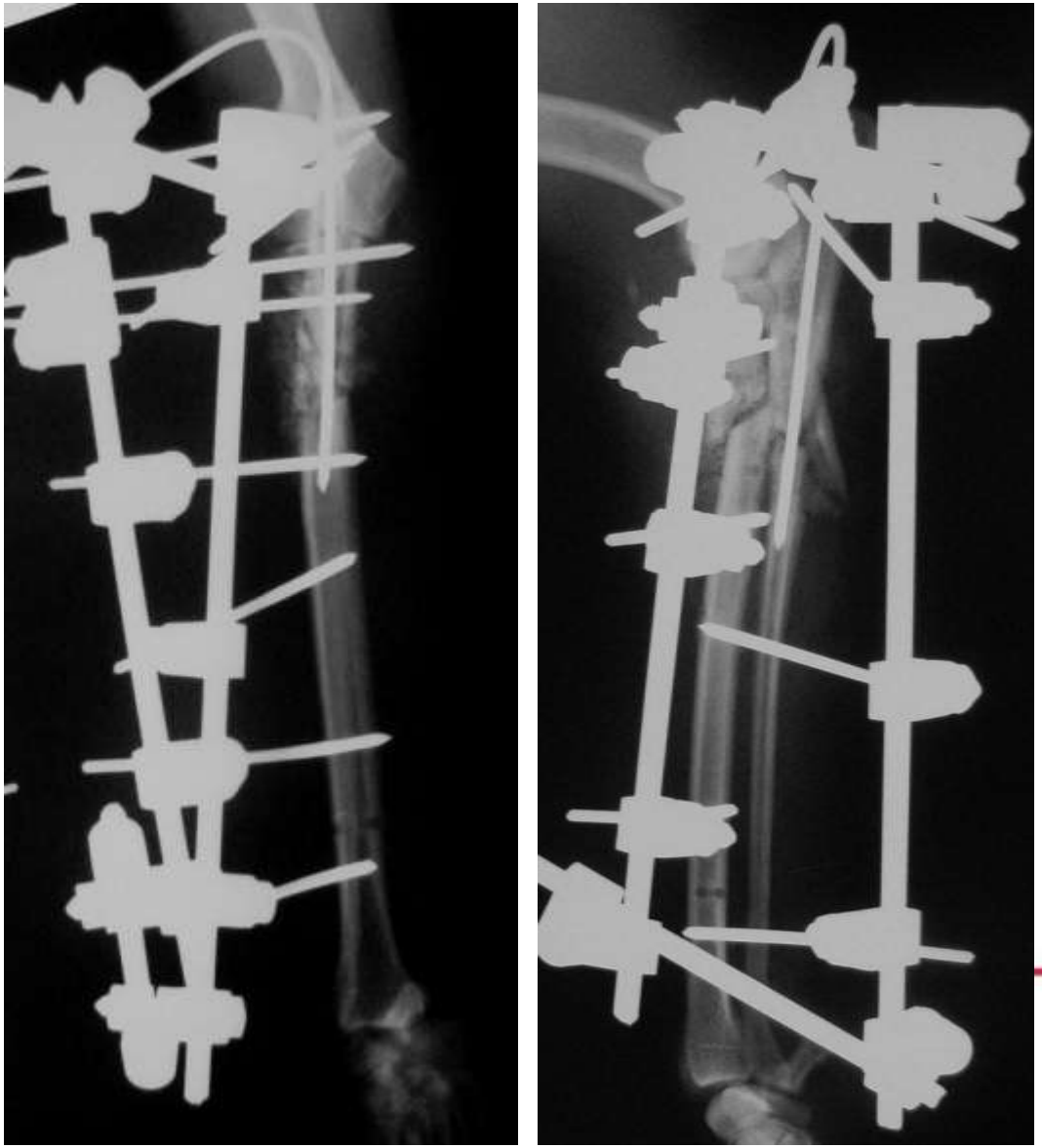

Radius / ulna

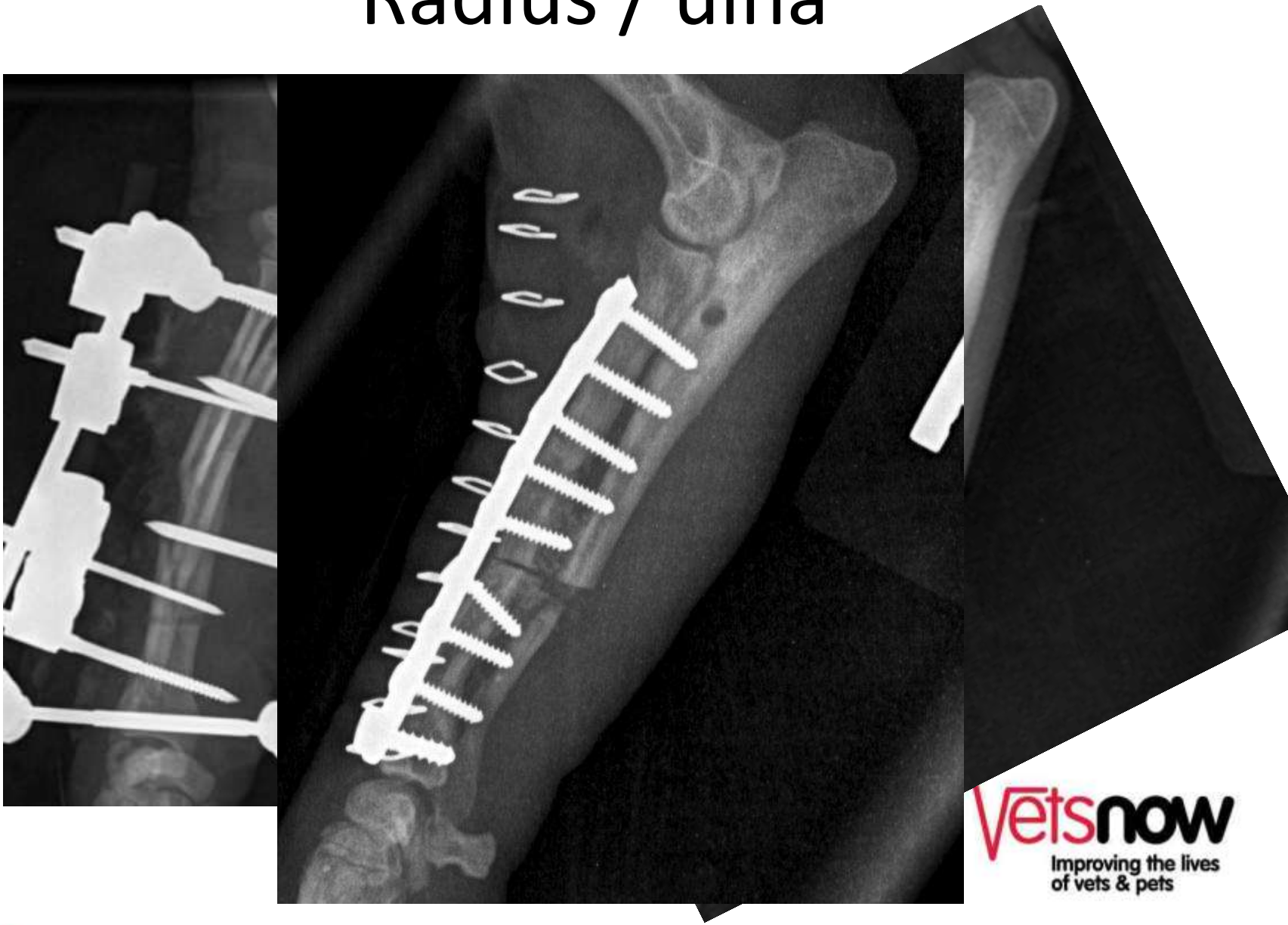

Femur

Femur

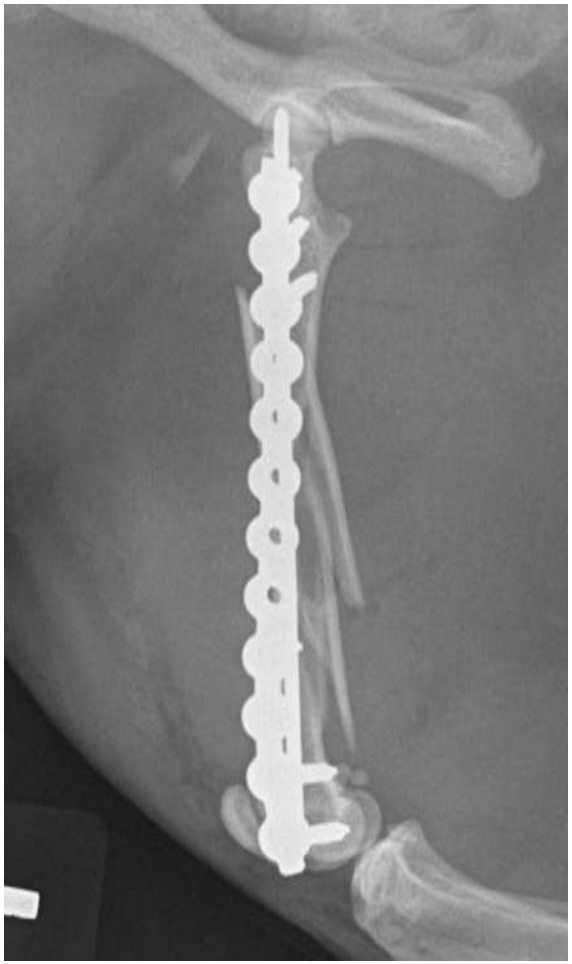

Tibia

Tibia

Tibia

Tibia

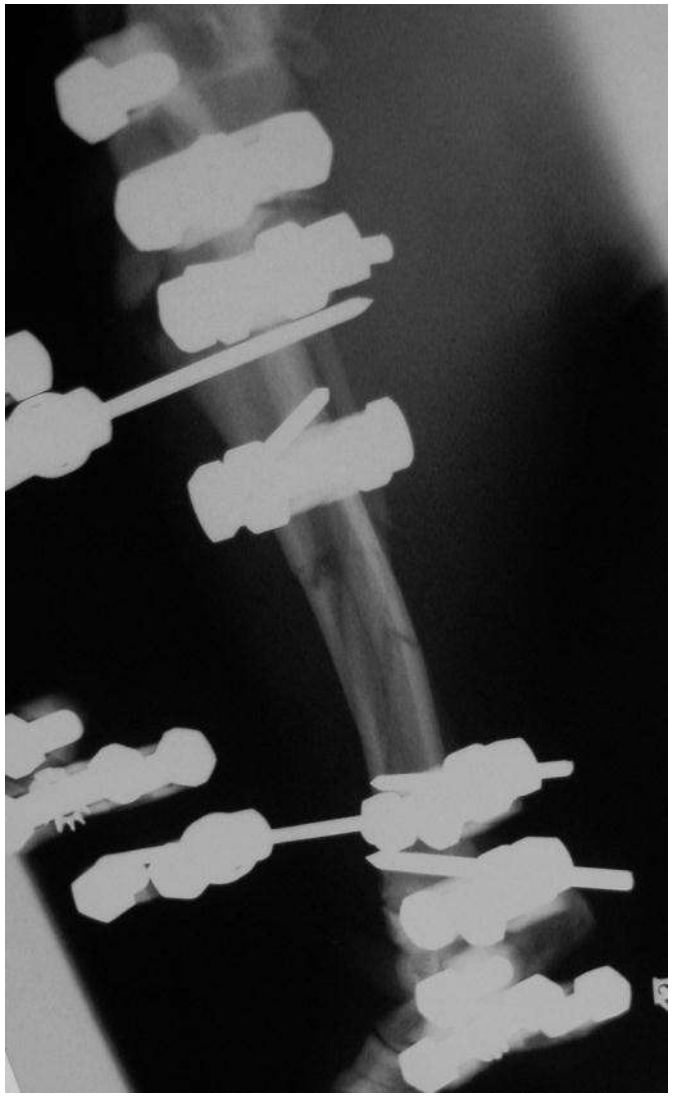

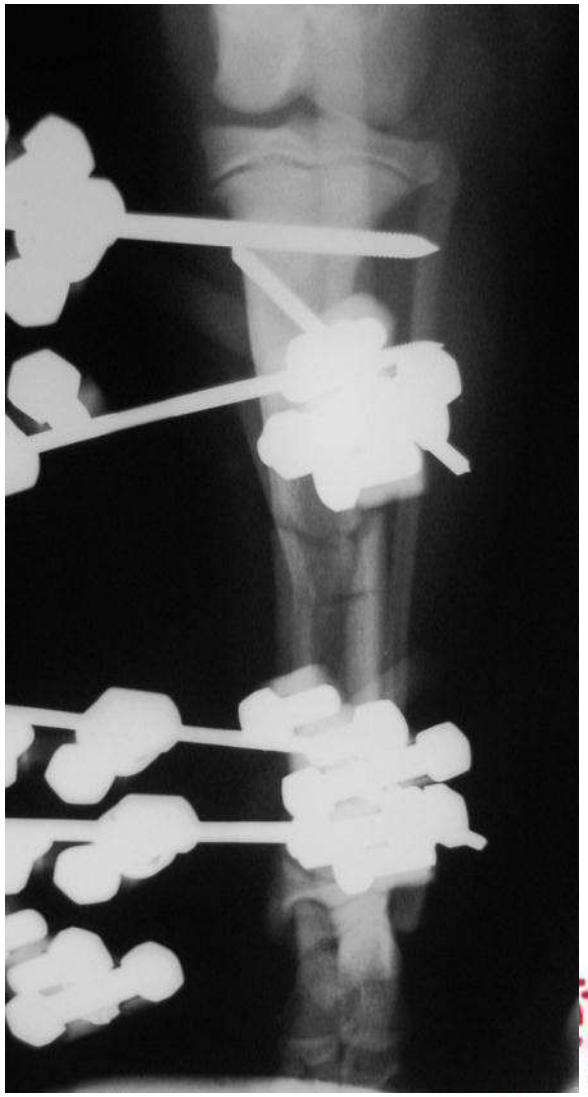

Other fracture applications

Mandibular fractures

Tarso-metatarsal luxation
(Plantar ligament intact)

Tarso-metatarsal luxation

Tarso-metatarsal luxation

Tarso-metatarsal luxation

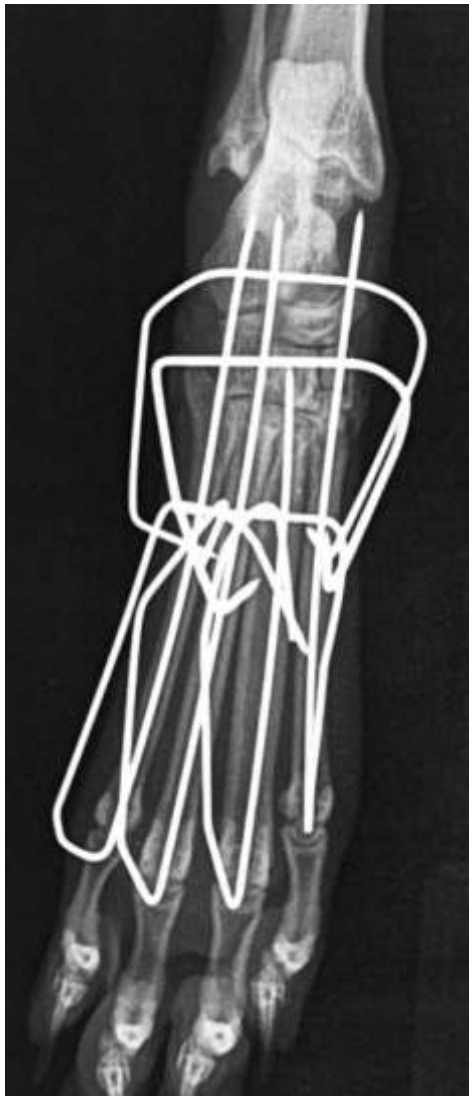

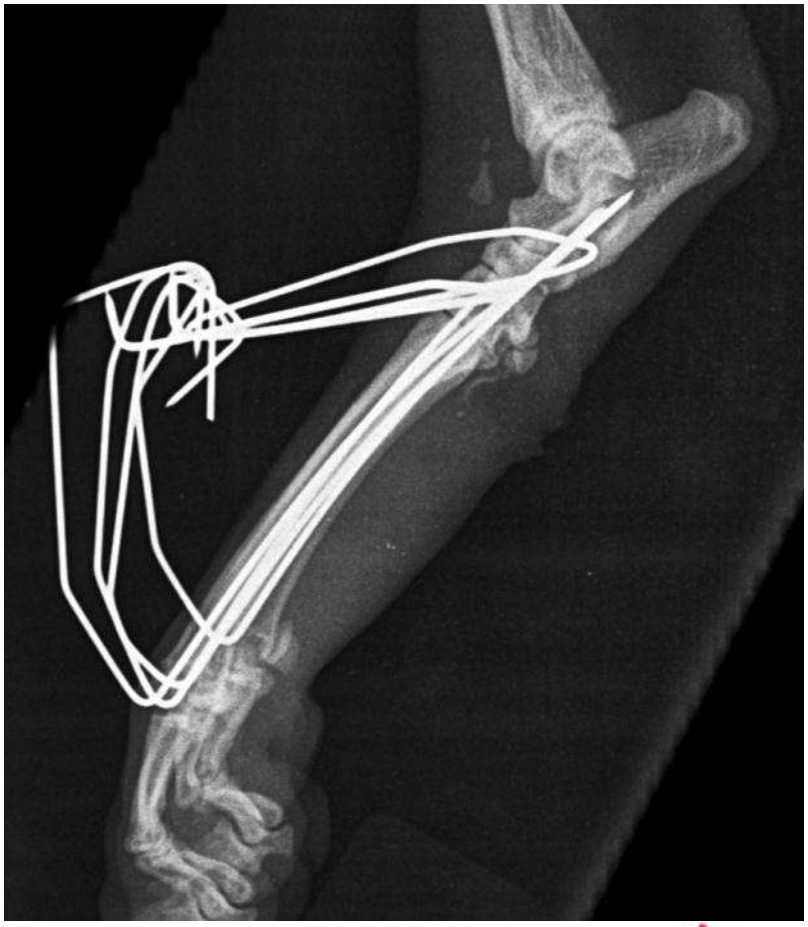

MT/MC Fractures

MT/MC Fractures

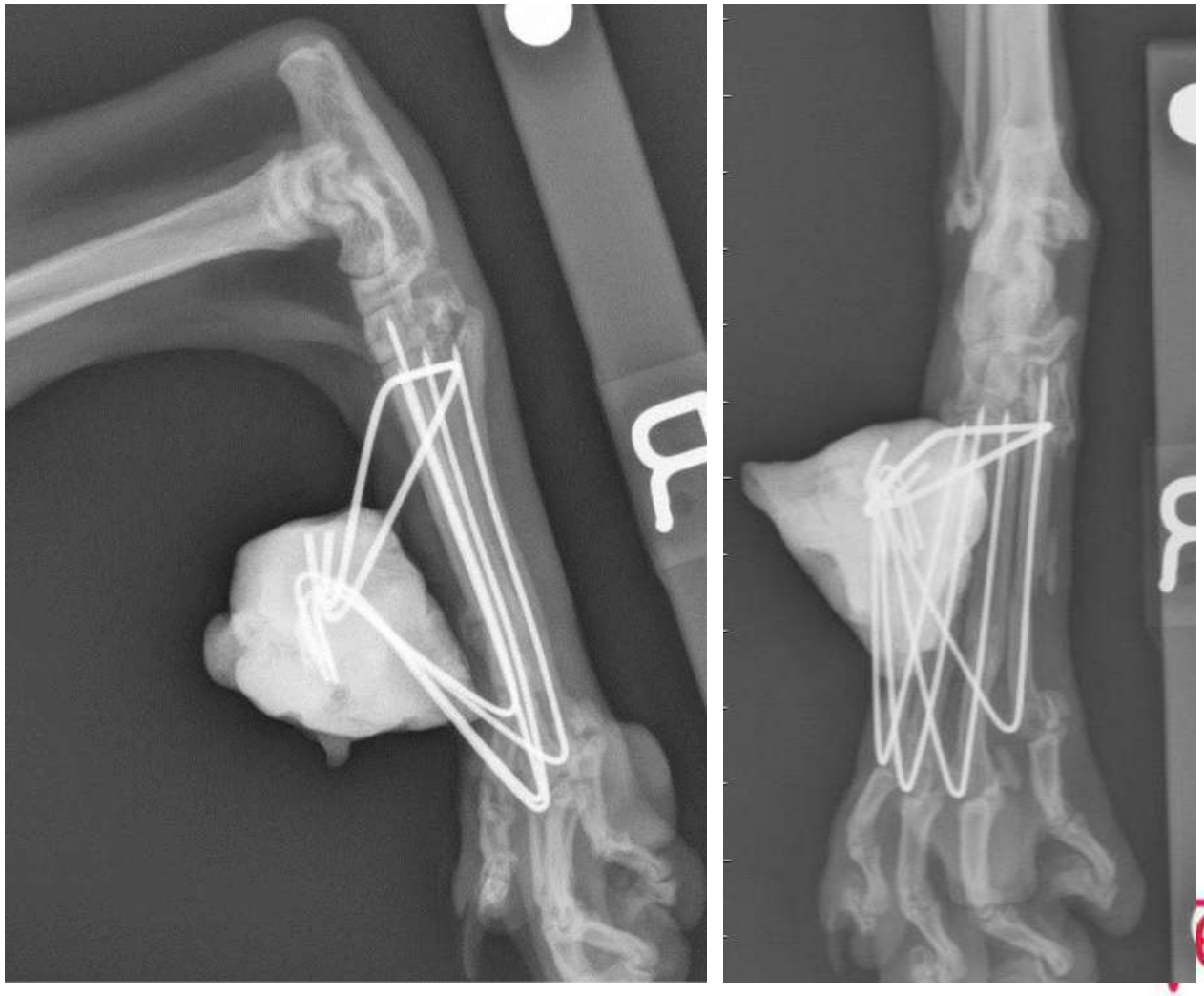

Surgical technique

- Dorsal approach
- K-wires directed retrograde through the fracture/luxation
  - exit MT bones at dorsal aspect of distal articular surfaces
  - driven distally until pin tip barely visible at fracture site
- Fractures/luxations reduced
- K-wires driven proximally into the MT
  - up to or through the TMT joints

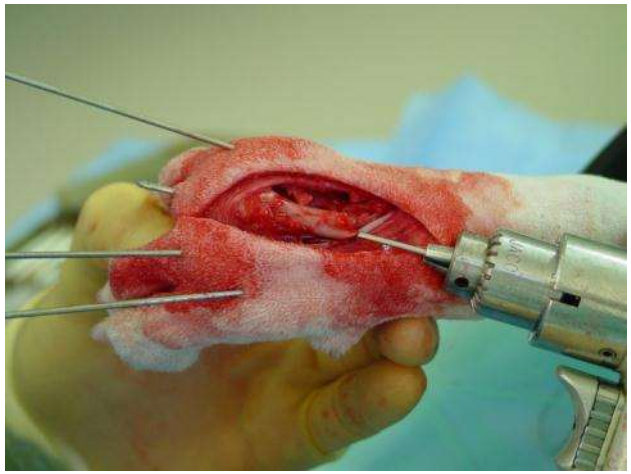

Surgical technique

- One or two pins placed transversely across bases of the MT or distal row of tarsal bones
- Pin ends contoured over dorsal MT
- Epoxy resin compressed over ends of K-wires to anchor frame
  - wooden tongue depressors used to space bolus away from skin
    - allow for post operative swelling
    - prevent thermal injury during curing

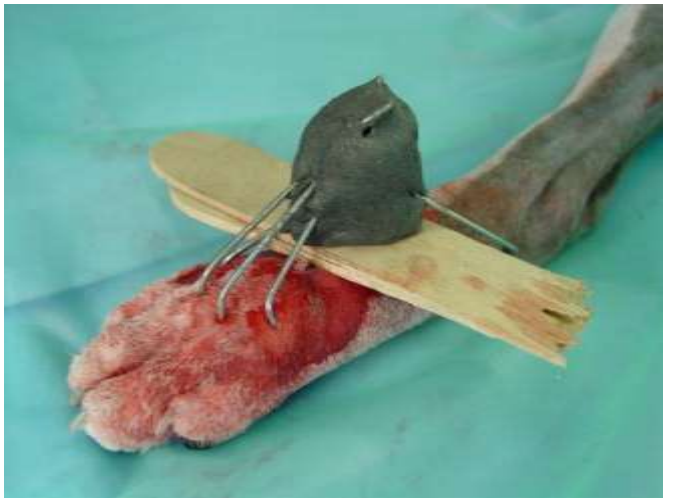

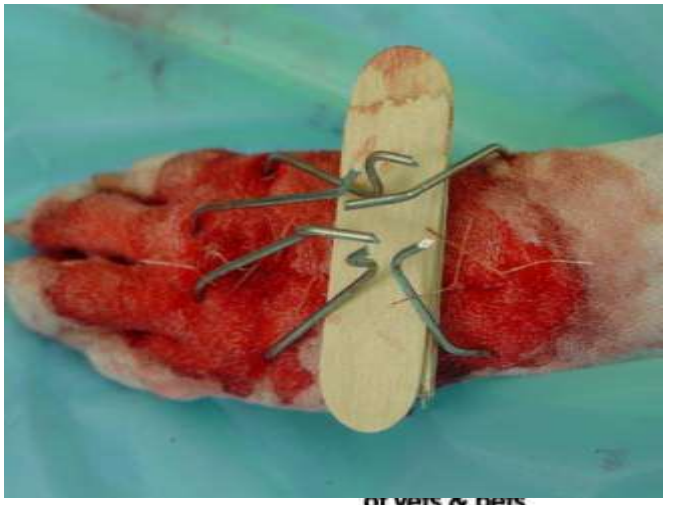

Pelvic ESF

Pelvic ESF

"No other type of fracture lends itself to iatrogenic trauma with so little to show for surgical interference as does the fractured pelvis" (Whittick,1974)

"With a little thought, patience and practice, the KE splint may successfully be used for the repair of pelvic fractures" (Knowles, 1949)

How does ESF management of pelvic fractures compare to conventional plate/screws?

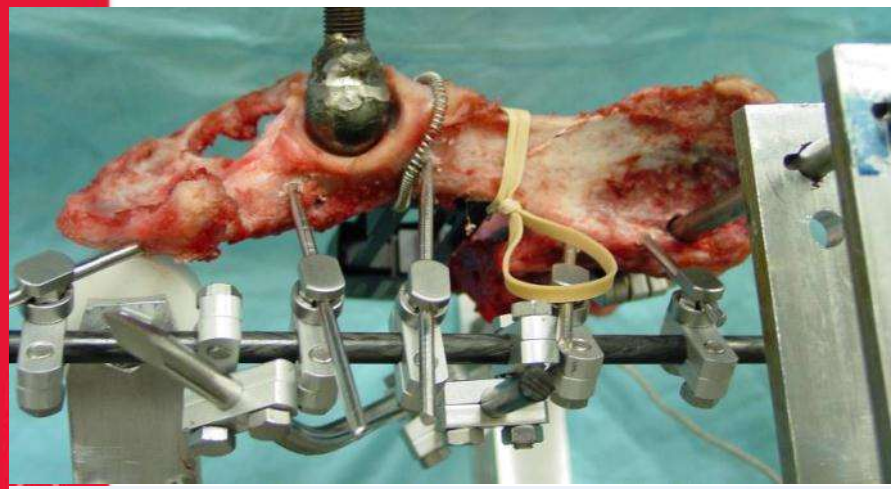

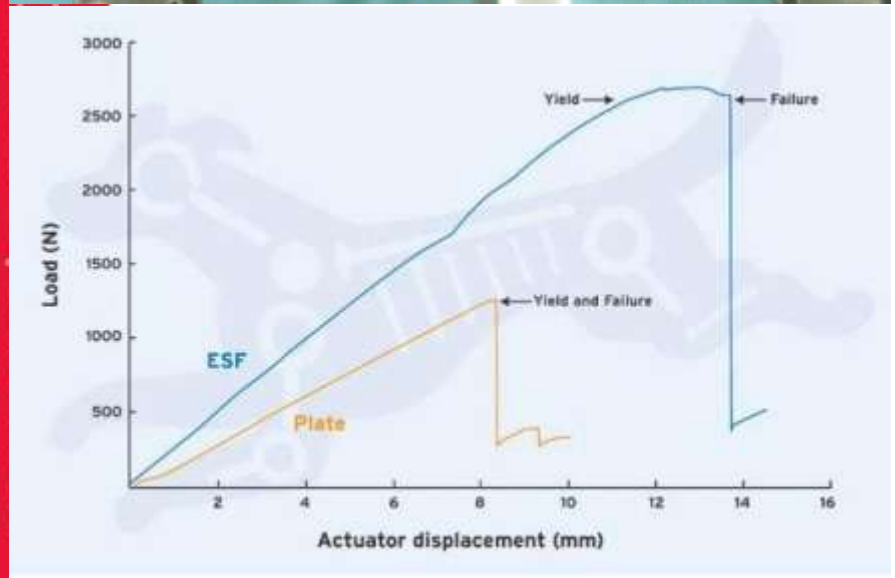

Typical load/displacement curves for paired hemipelves stabilised by external skeletal fixator and plates & screws

- Mechanical Factors

Application of EF to ilial fracture is superior to plate/screws in terms of yield and failure and is of comparable stiffness

Hip luxation

- Coxo-femoral luxation: customized hinge units mounted from frame → pin driven into the proximal femur

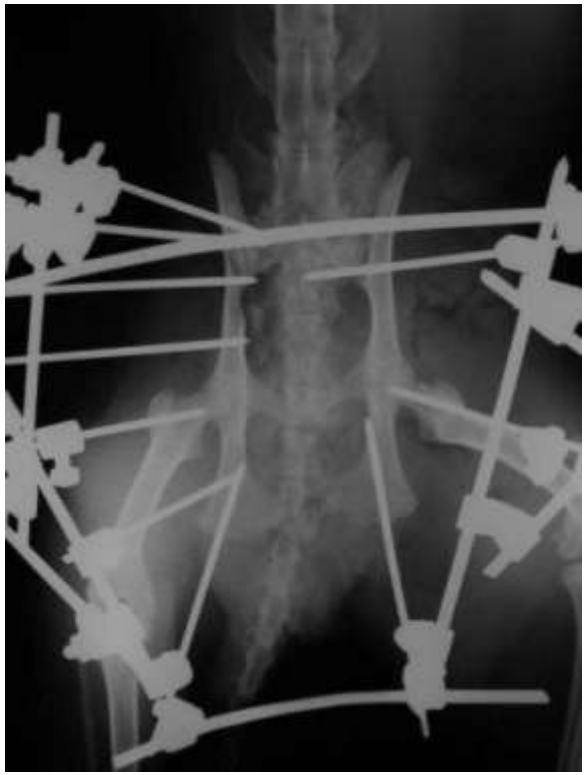

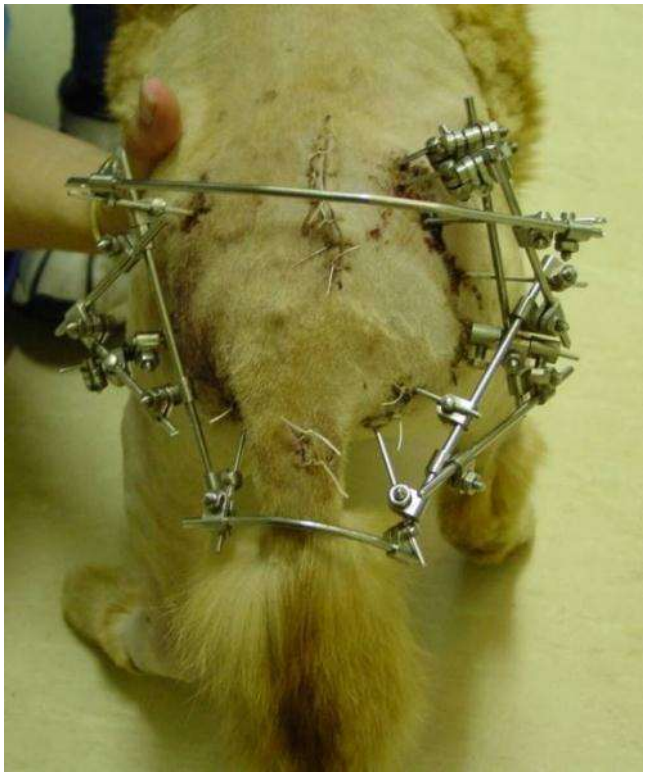

Spinal application

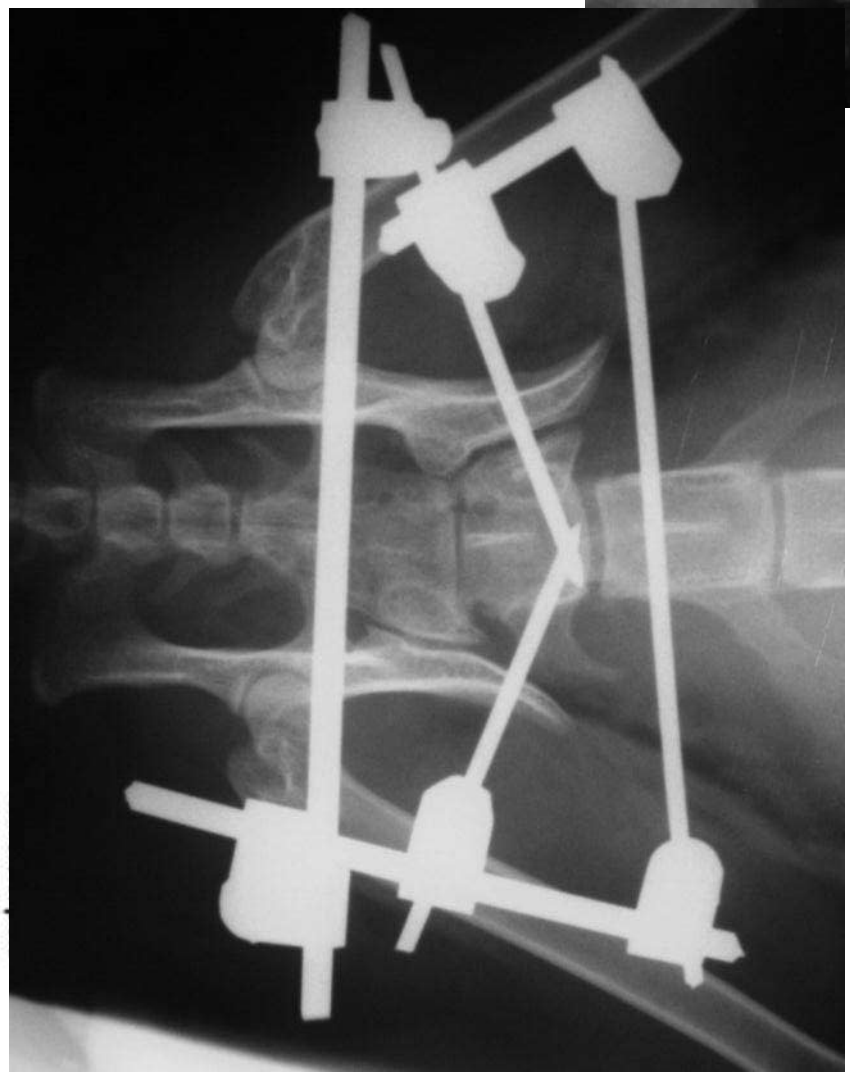

Non-fracture applications

Hock instability

Stifle Disruption

Stifle Disruption

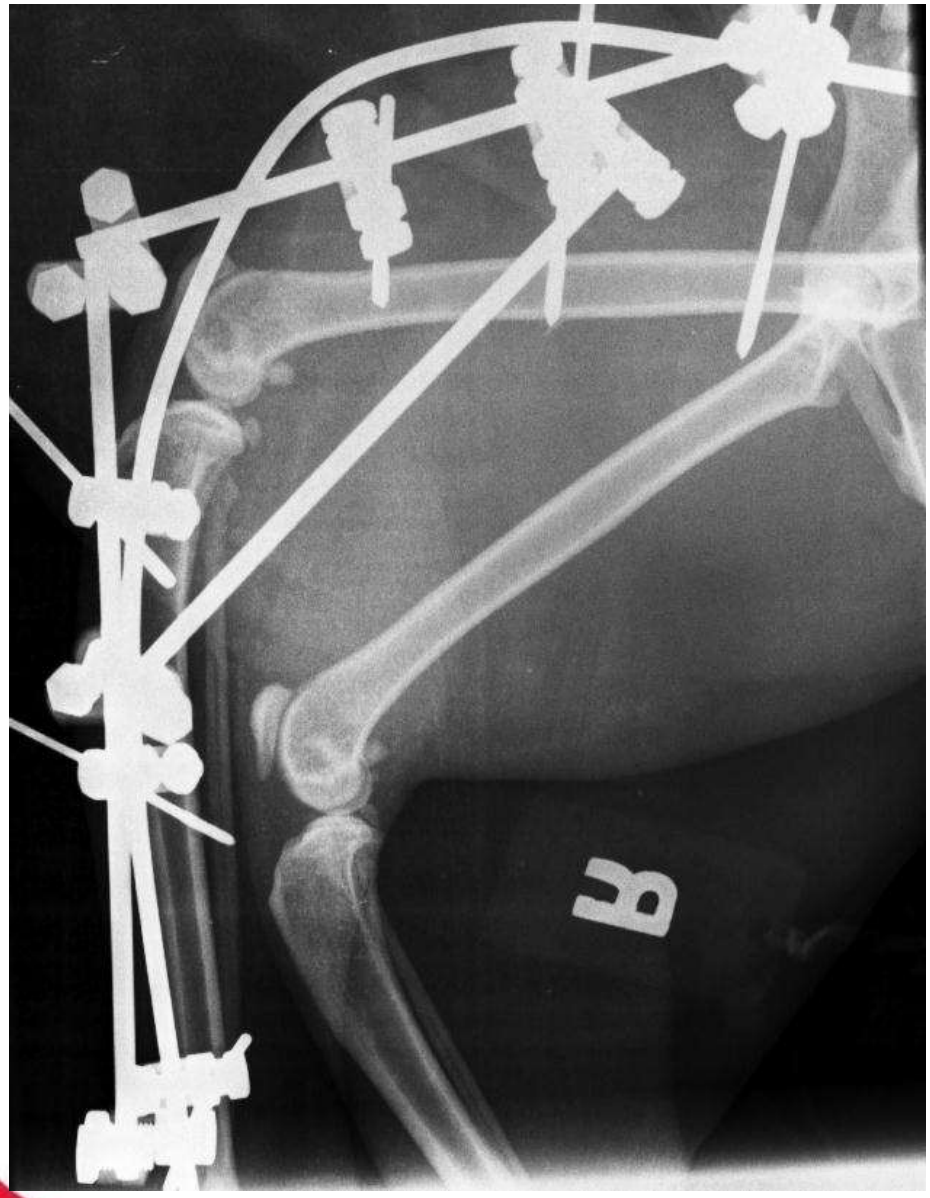

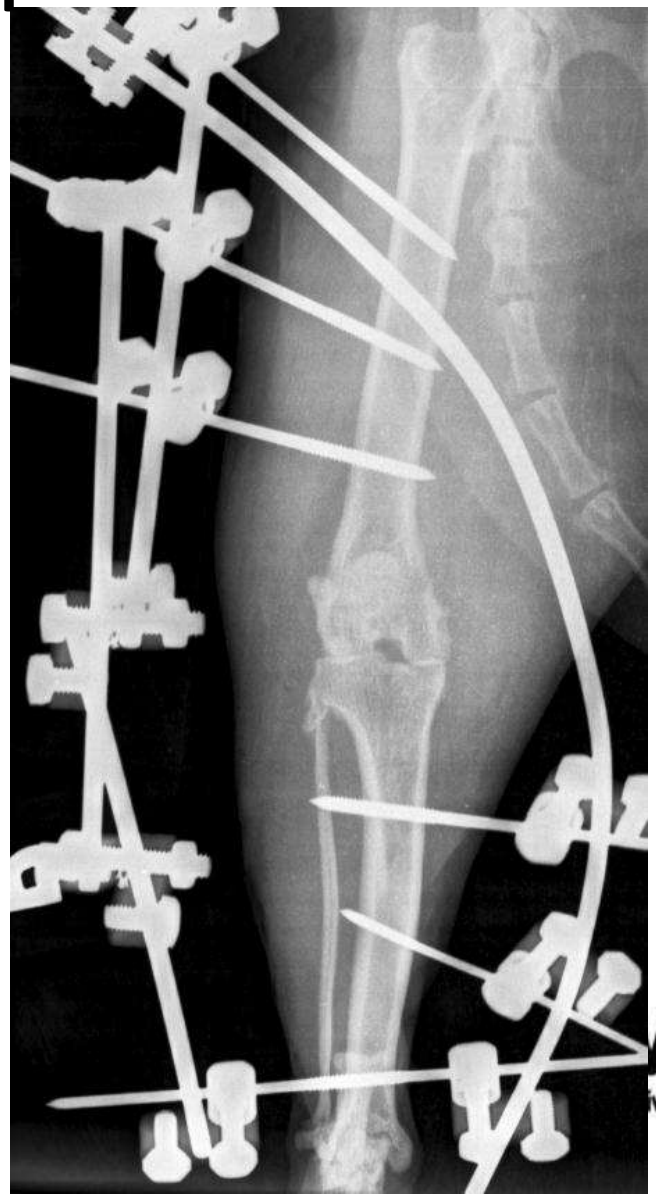

Limb deformity management

Can get complicated…

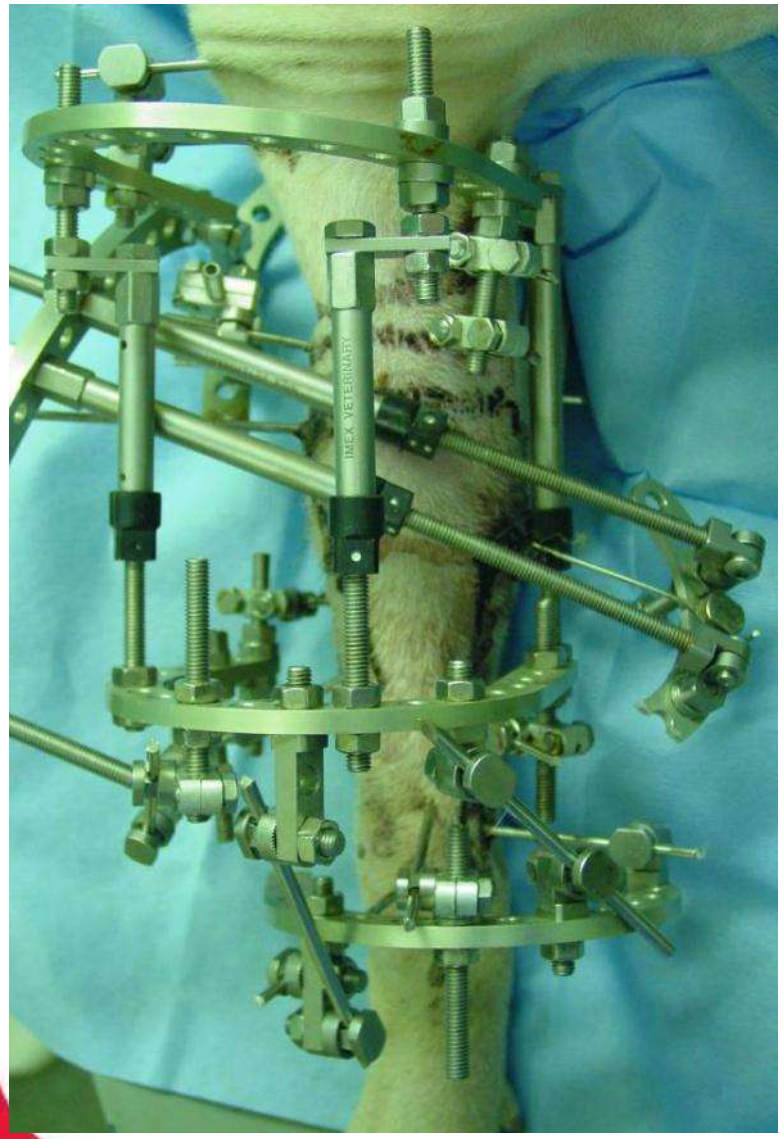

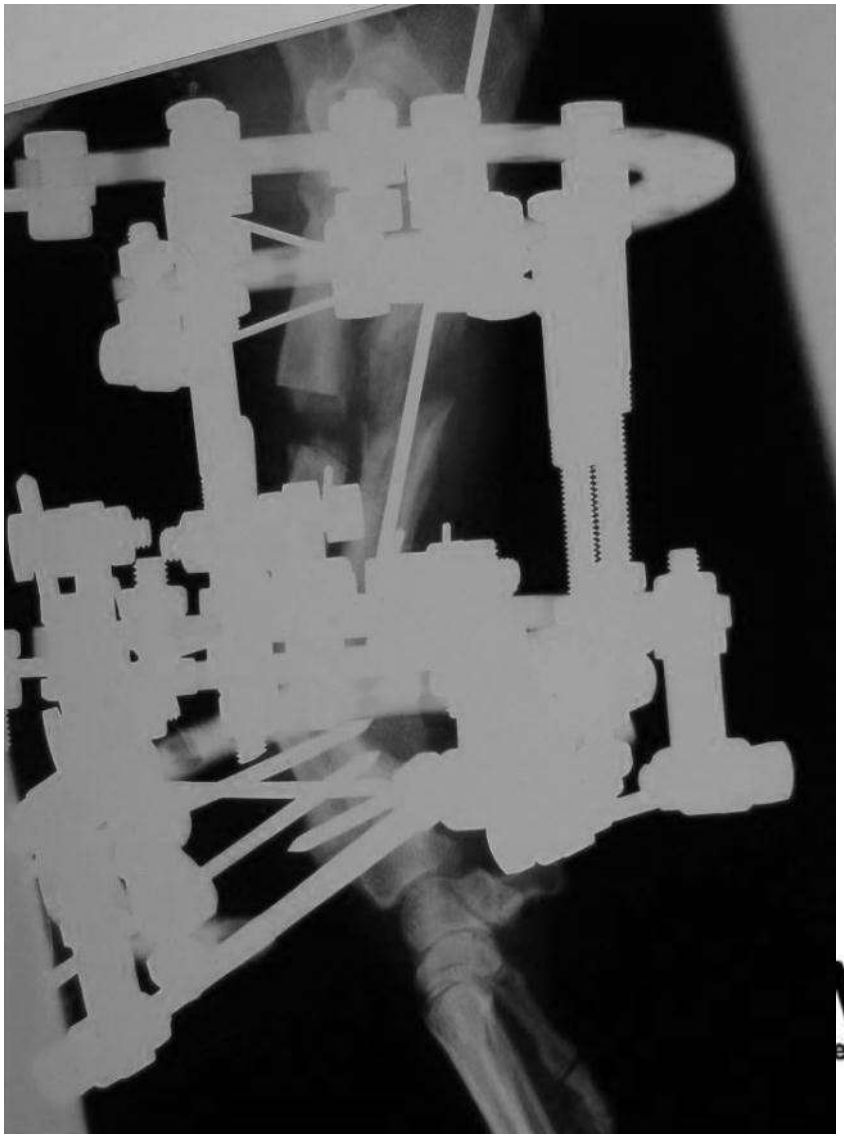

Pedal Arch Wire Scaffold (PAWS)

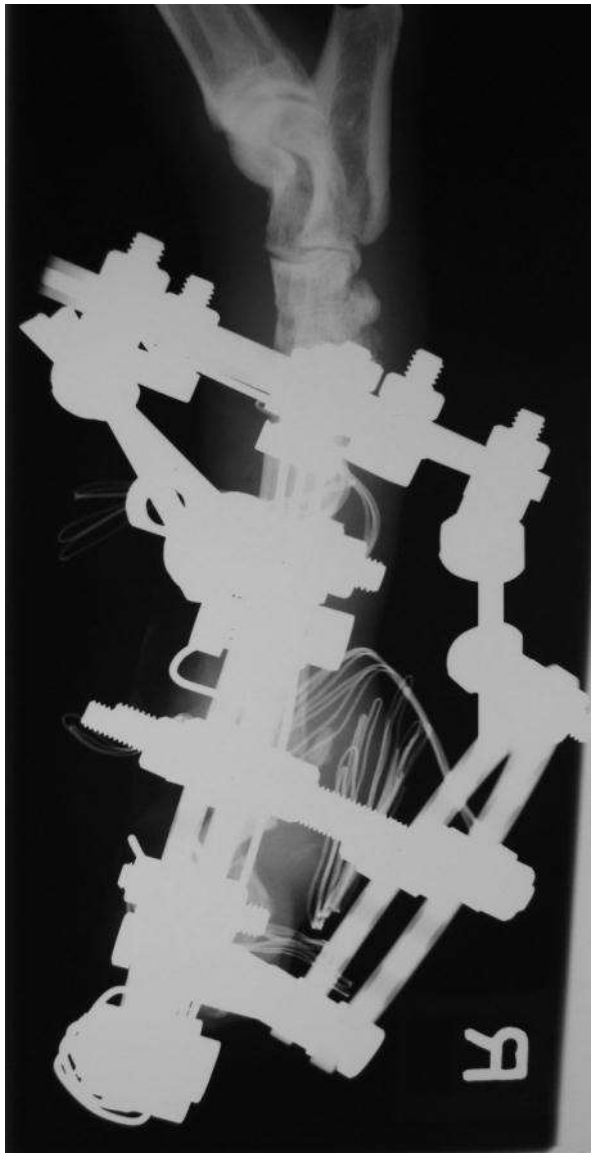

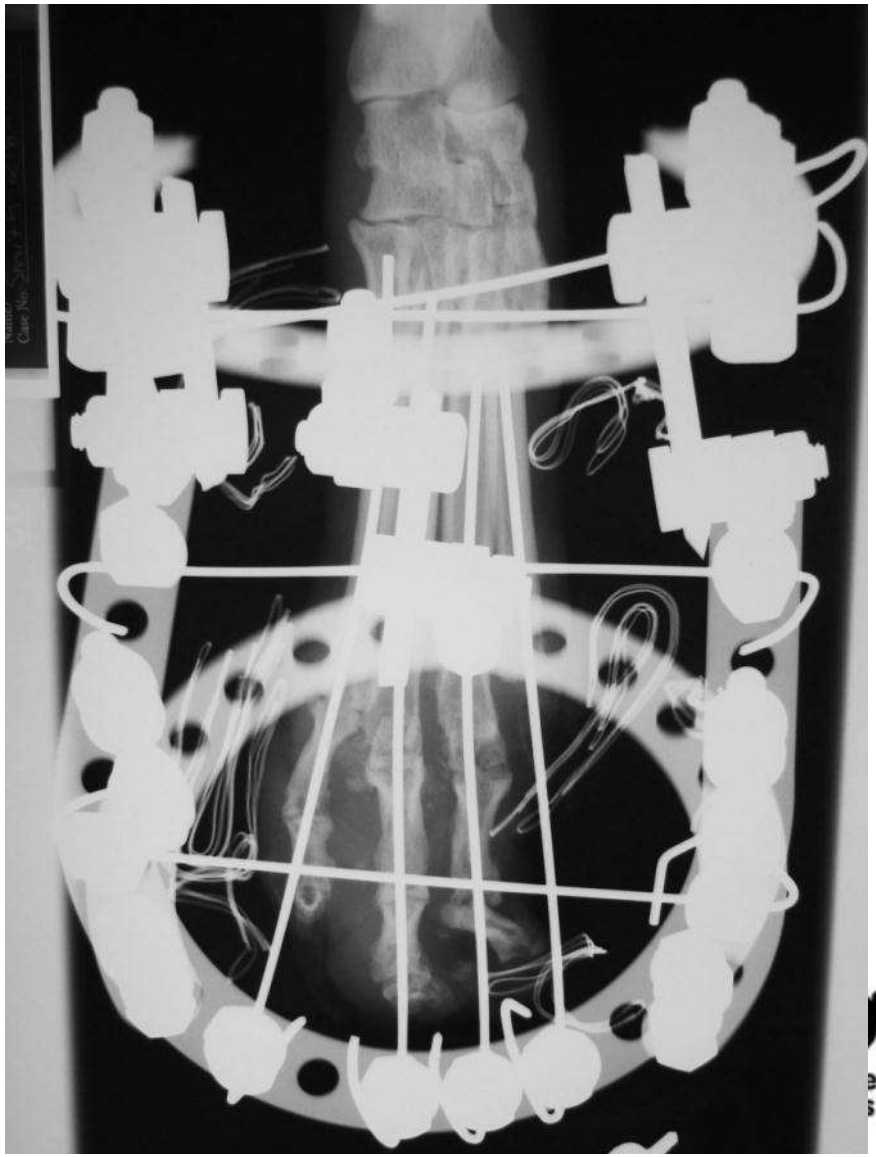

Neurogenic injury subsequent to sensory neuropathy (trophic ulceration)

PAWS used to protect foot during renervation

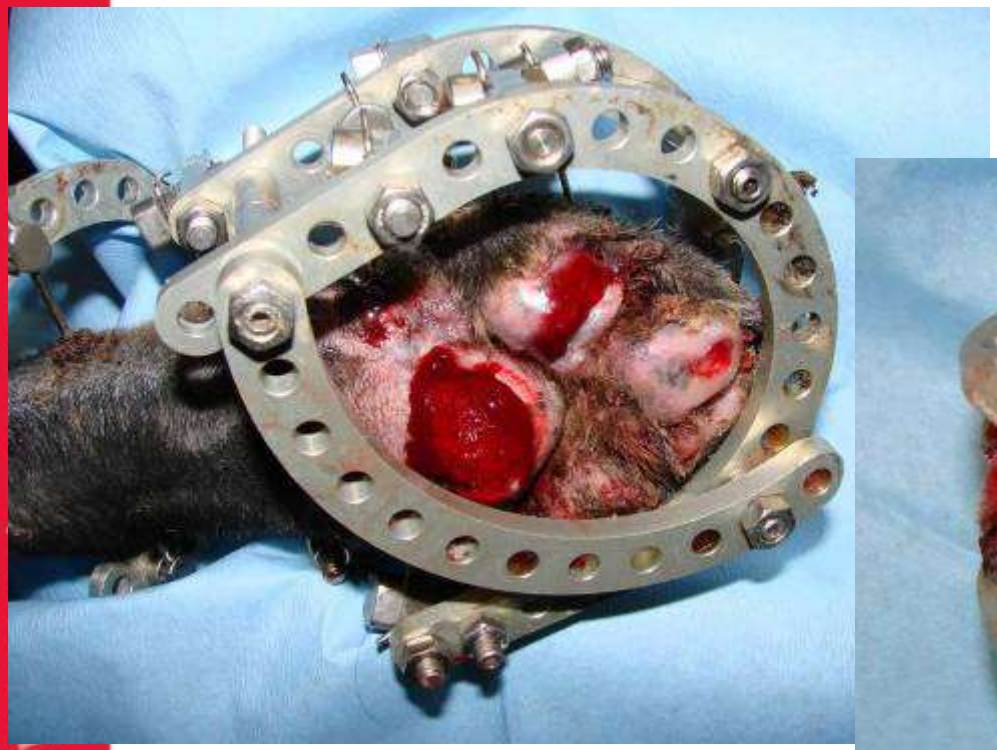



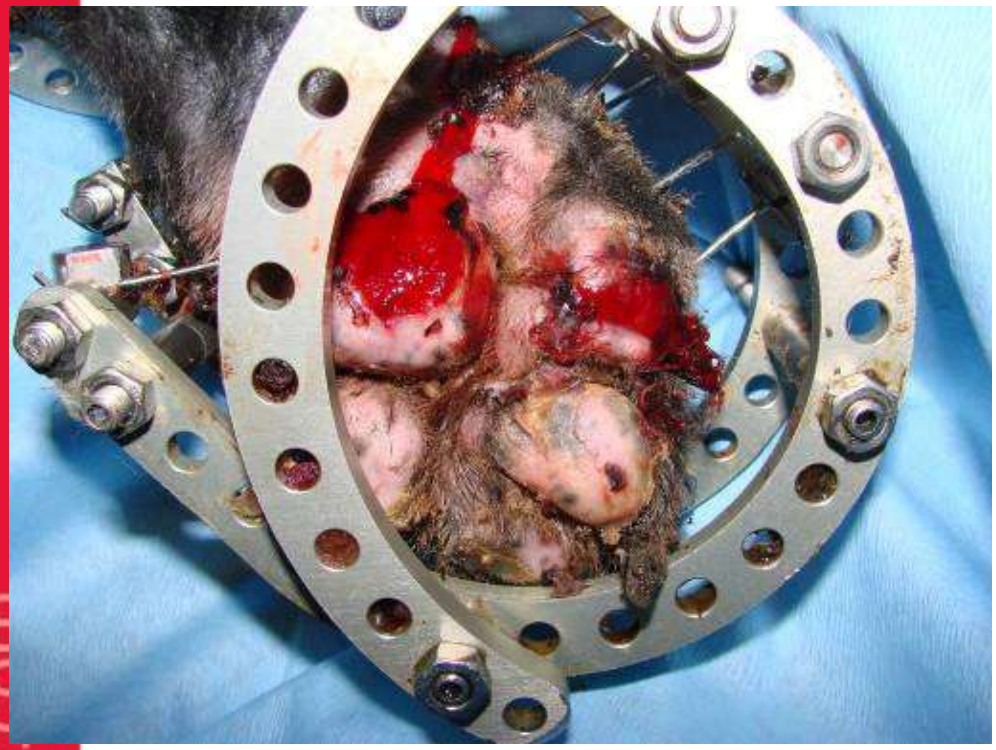



Take home messages - ESF

- Choice of fixation technique based on understanding of specific fracture biology and mechanics
  - Careful case selection
  - Preservation of biologic potential essential
- Extremely versatile
- Familiarity with range of implants / ESF systems (and respective properties) important

Questions

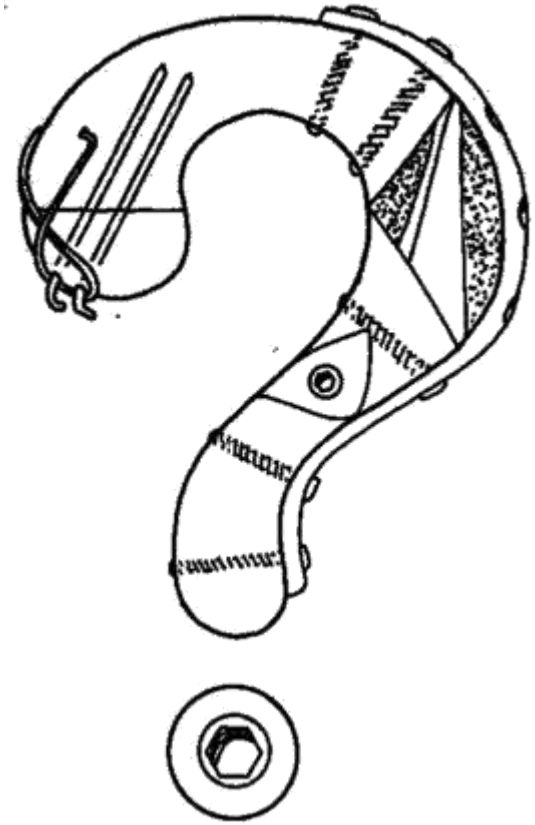

VETERINARY INSTRUMENTATION
A HENRY SCHEIN® COMPANY

Vetsnow
Improving the lives of vets & pets